

## Kinesiology Taping Techniques for the Upper Extremity

Kristin Valdes, OTD,OT, CHT  
Marybeth Laplant, PT, CHT  
Mary Loughlin, OTR/L,CHT,CKTP

### Evidence?

- Despite its popularity and widespread clinical use, there is relatively little evidence to support the effectiveness of elastic therapeutic tape/ Kinesiotape, let alone for specific neck and upper extremity conditions
- A scoping review of the use of elastic therapeutic tape for neck or upper extremity conditions
- Journal of Hand Therapy
- 2014
- Taylor et al.

### Reviewed

- Of the 14 studies that were included in this scoping review, seven articles were randomized controlled trials (RCTs), four were single-group repeated measure studies, two were quasi-experimental studies, & one was a case report
- Looked at the impact on taping on
  - Pain
  - Motion
  - Strength
  - Patient Preference

### Pain

- Six out of eight studies that examined changes in pain for carpal tunnel syndrome, biceps tendonitis, medial epicondylitis, rotator cuff pain, neck pain and shoulder pain found statistically significant differences in favor of elastic therapeutic tape
- But....
  - No long term follow-up measurements obtained
  - elastic therapeutic tape may be able to provide an immediate short-term reduction in pain

### Impact on range of motion

- Four of these studies involved changes in shoulder range of motion and two studies examined cervical range of motion. Of these, three studies found statistical significance for increased range of motion.



### Impact on strength

- Three studies (one with a healthy athlete population, and two with athletes with upper limb conditions) examined changes in strength. Two measured grip strength, and one lower trapezius muscle strength following immediate application of elastic therapeutic tape. All found no statistically significant difference between groups.



### Patient preference

- Only one study examined patients' preference of elastic therapeutic tape compared to an alternative intervention (in this case, bandaging for lymphedema management). They found statistically significant results to support the argument that elastic therapeutic tape was preferred by participants ( $p < 0.05$ ). Reasons included longer wearing times, less difficult usage, increased comfort and convenience.



### Benefits of Taping

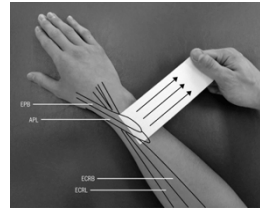
- Another benefit that was found as part of this scoping review was that elastic therapeutic tape is a treatment modality that has few side-effects. No adverse events were reported in any of these studies as a result of the use of elastic therapeutic tape.
- The findings of this scoping review suggest that elastic therapeutic tape may play a role in reducing short-term neck and upper extremity pain and that it may be a more convenient and comfortable alternative to existing conservative treatments.

## Kaneko, S & Takaski, H JOSPT 2011

- Forearm Pain, Diagnosed as Intersection Syndrome, Managed by Taping: A Case Series

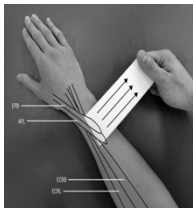


## Taping Technique



- The taping direction for each patient was determined by assessing crepitus during thumb movements, while manual force was applied across the soft tissue of the dorsal aspect of the forearm.

## Taping Technique



- Tape was then applied in an attempt to replicate and maintain the manually applied force across the muscle-tendon unit. The distal end of the tape was applied first to the muscle bellies of the APL and EPB. Tension was exerted with the free end of the tape as it was applied across the dorsal forearm, perpendicular to its long axis
- A 2<sup>nd</sup> layer of tape was used to reinforce the 1<sup>st</sup> layer

## Application and Wearing of the Tape

- The tape was removed at night, and each patient was instructed to maintain the taping regimen for 3 weeks and allowed to continue work.

The patients were also advised to perform their normal daily activities. Following the 3-week intervention, all patients were advised to use the symptomatic limb during activities of daily living and to work without tape. They were instructed to reapply the tape if they had any return of symptoms

## Outcomes

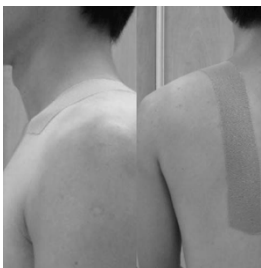All patients reported a complete elimination of crepitus with the application of tape. Crepitus induced by wrist movements, tenderness over the dorsal forearm, and swelling were no longer present at 3-week follow-up. Disability identified by the disability/symptom subscale of the Disabilities of the Arm, Shoulder and Hand questionnaire decreased at 3-week follow-up, and this reduction was maintained at 4-week and 1-year follow-ups.

## Scapular Taping

- Lin et al showed taping caused increased serratus anterior activity and decreased upper trapezius activity while there was no effect on lower trapezius




## Tape Application




- Used an "I" shaped Kinesiotape
- Subjects were asked to fully retract and depress their scapula and maintain the posture.
- At the same time, we applied the Kinesiotape from the inferior margin of the medial 1/3 of the clavicle to T12 with full stretching of the tape

## Shoulder taping to improve ROM

- The results suggest that KT can increase shoulder ROM. Stretching was not found to have an effect on shoulder ROM, regardless of whether it was used alone or in combination with KT.



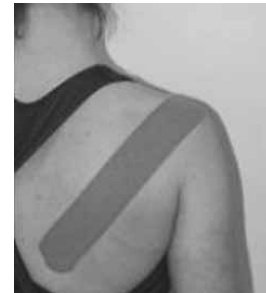### Tape needed



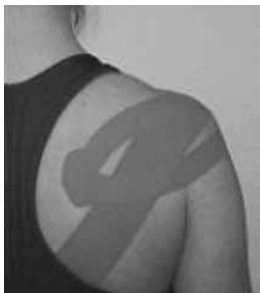- One "I" strip of tape cut  $\frac{1}{2}$  lengthwise until  $1\frac{1}{2}$  inches from one end
- One "I" shaped piece

### Technique

- One "I" strip of tape covered the skin surface from the anterior portion of the glenoid rim to the inferior border of the surface from the medial portion of the spine of scapula to the anterior portion of the glenoid rim with 50% stretch

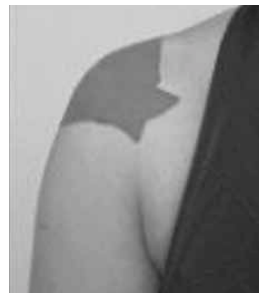

### Y strip



- The upper portion of the "Y" strip was pulled diagonally in a superior and anterior direction. Prior to application of the lower portion, the shoulder was positioned in ER

### Anterior View



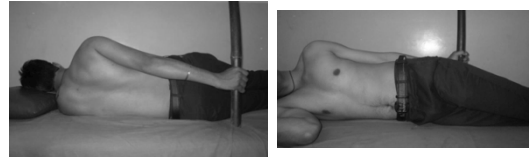
- Analysis of variance identified a significant difference among groups for the magnitude of change in shoulder ROM,  $F(2, 68) = 3.268$ ,  $p = 0.044$ , and the
- KT group demonstrated the greatest increase in ROM between day 1 and day 4

## To Improve ROM with Adhesive Capsulitis

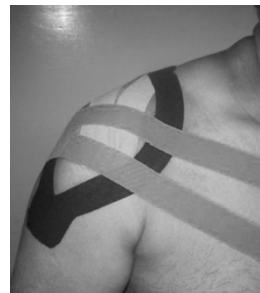
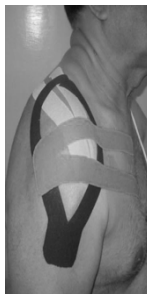
- Kinesiotape with CHL positional stretching is effective in overcome pain and disability in patient suffering from adhesive capsulitis.

Initially the duration of stretch is applied for 5 min and progressed to 15 min by the end of second week

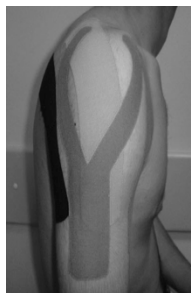

- For deltoid muscle; a kinesiyo Y strip is applied with paper-off tension from insertion to origin. The first tail of y strip is applied to the anterior Deltoid with the arm in horizontal abduction and external rotation, along the outer border of the anterior deltoid to acromioclavicular joint. The second tail is applied to posterior deltoid with the arm in horizontal adduction and internal rotation, along the outer border of posterior deltoid to the acromioclavicular joint. Last 2 inches been applied without tension. For assisting external rotation by releasing tension of internal rotation; kinesiyo Y strip is applied to the base of posteriolateral border of humerus



- Very light to light tension (15-25%) is applied to the tails of the kinesiyo Y strip. The superior tail is applied inferior to clavicle and end of the sternoclavicular joint and the inferior tail is applied following the lower fibers of the pectoralis major to the costochondral joint

- Lastly, we performed the taping of the teres minor muscle. The I-type strip was placed on the lower facet of the greater tuberosity of the humerus with no tension. Then, the patient abducted the shoulder in horizontal flexion with internal rotation. We placed the rest of the strip along the axillary border of the scapula with light (15–25%) tension



## Kinesiology Taping vs. Athletic Taping

### ATHLETIC TAPING

- Stabilization
- Restrictive/supportive
- Restricts fluid exchange
- Worn a few hrs
- Examples: McConnell tape, Leukotape, Endura Sports Tape

### KINESIOLOGY TAPING

- Stabilization
- Allows mobility
- Increased circulation
- Withstands fluids
- Can be worn about 3 days
- Examples: Kinesiotape, Rock Tape, Spider Tech

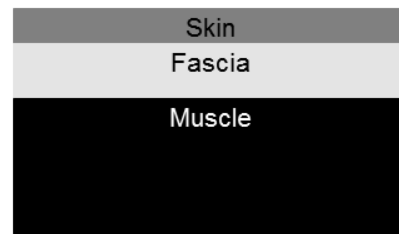## Kinesiology Taping

- Elastic properties
- Weight, thickness, elasticity of tape similar to skin
- One way longitudinal stretch
- Allows free movement and for normal tissue expansion

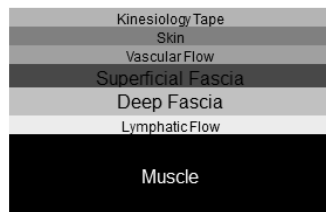
## Kinesiology Taping benefits

- Provides support
- Reduces muscle fatigue
- Stimulates muscles to strengthen when weak
- Afferent Sensory Stimulation (pain relief)
- Increases vascularity/improves lymphatic flow (clearing inflammation)
- Promotes movement across kinetic and fascial chains

With inflammation, tissue restrictions or other limitations, there becomes increased resistance and decreased space between the skin, fascia and muscle.



Fascial Adhesion



Kinesiology Taping

### Contraindications/Precautions

- DVT
- Open Wounds
- Infection
- Fragile/sensitive skin
- Heart Failure
- CHF with edema
- Respiratory Conditions
- Diabetes
- Kidney Disease
- Ulnar side of elbow (caution due to ulnar nerve)
- Currently under treatment for Cancer
- Pregnancy
- Skin irritation



### Things to remember

- Tell pts never blow dry the tape
- Tell pts do not use hot packs or heat treatments with the tape on
- No oils or lotions on skin when applying
- May need to shave hair off the affected area to have good contact
- Check skin before applying

### General Principles

- Anchors/ends are applied with no tension
- Tape is made to stretch in the longitudinal direction only
- Tape can be left on 3-5 days
- Skin needs to rest at least 24 hrs after tape application, before reapplication.
- Remove tape immediately and gently if irritation/sensitivity. (can do 24 hr. test patch with no tension)
- Teach pts how to remove the tape.
- Must wait 30 min before going in a pool or doing a sweaty workout in order for tape to adhere well.

### Stretch and Recoil Principles

- Stretch the tape away from the anchor and the tail will recoil back to the anchor
- To encourage shortening of a muscle (to facilitate) apply tape ORIGIN to INSERTION
- To encourage elongation of a muscle (to inhibit) tape INSERTION TO ORIGIN.
- In cases of edema applications, lymphatic flow will be directed towards the anchor

Anchor	Tail	End
No tension	Portion of tape where tension is applied	No tension
Typically 1-2 inches		Typically 1-2 inches
In case of higher tension(>50%), use rule of thirds		In cases of higher tension(>50%), use rule of thirds

### More General Principles


- Majority of techniques 15-25 percent tension. (Most skin irritation due to too much tension.)
- Rule of thirds for higher tension taping (>50% tension)
- For all basic application techniques, the muscle/tissue to be treated should be put in a stretched position in combination with the stretch capabilities of the tape. This will create convolutions as the skin is lifted.

### Basic Tape Cuts



- I strip: Tension is focused within the therapeutic zone directly over the target tissue
- Y strip: tension is dispersed through and between two tails over target tissue
- X cut: Tension is focused directly over target tissue and dispersed through tails
- Fan cut: Tension is dispersed to over target tissue through multiple tails

### Shapes of Tape Cuts



### Buttonhole cuts

- Can be used so that the tape can be anchored over the digits



### **Tape Application**

- Prior to taping, make sure skin is clean
- Round edges of tape
- Typically the joint is moved through a full active or passive motion to provide a stretch on the tissue while tape is applied. In some cases, alternate positioning may be recommended.
- Lightly rubbing the tape activates the adhesive

### **Removal of Tape**

- Remove in direction of hair growth
- May gently roll it off the skin using 1 hand while other hand supports the skin
- May be removed while showering or in a bath
- Can use baby oil, canola oil, moisturizer, hand lotion to assist with tape removal

### **Types of applications**

- General muscle applications
- Advanced Corrective techniques
  - mechanical correction
  - fascia correction
  - space correction
  - ligament/tendon correction
  - functional correction
  - lymphatic correction

### **How much tension?**

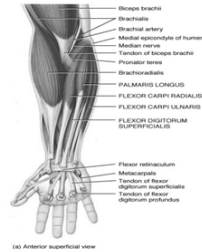- Paper off tension=10-15%
- MUSCLE APPLICATIONS-to inhibit 15-25%, insertion to origin  
-to facilitate 15-35%, origin to insertion
- ADVANCED TECHNIQUES
  - Space correction-10-35%
  - Fascial correction-10-25% for superficial fascia (advanced oscillating technique)
  - Lymphatic correction-0-20%
  - Tendon correction 50-75%
  - Functional correction ("spring assist" or "limit")50-75%
  - Mechanical correction ("postural hold") 50-75%
  - Ligament correction 75-100%

### Case study-CTS

- 50 year old woman complains of paresthesias in the thumb, index, and middle fingers
- Her CTS symptoms have been exacerbated with a full day of paddling/boating
- What type of taping technique would you recommend?

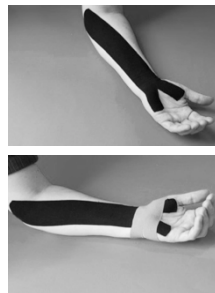### Flexor Complex

- Origin: Common Flexor Tendon/ Medial Epicondyle
- Insertion: multiple attachment sites: metacarpal, pisiform, etc on palmar surface
- Action: wrist flexion



### CTS

- Measure from palm of hand to medial epicondyle. Apply tape distal to proximal, with 15-25% tension, while wrist and fingers are extended.
- Measure 2/3 around wrist. Apply 15-25% tension over carpal tunnel while wrist extended.

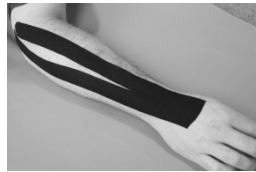


### Case study-lateral epicondylitis

- 41 year old male complains of localized pain at the lateral epicondyle, and trigger points and myofascial restrictions in the proximal forearm musculature after recent performing of repetitive throwing drills with his son's baseball team.
- What kind of taping would you recommend?

## Lateral Epicondylitis

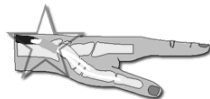- Measure distal to 2<sup>nd</sup> and 3<sup>rd</sup> metacarpal insertion region to lateral epicondyle. Cut "Y" leaving anchor uncut.
- Apply distal to proximal with 15-25% tension while wrist is flexed and elbow extended.



## Case study-Dequervain's

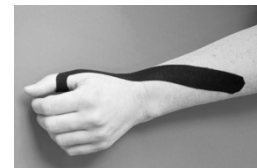- 31 year old dental hygienist progressive onset of pain in first dorsal compartment
- Positive finklesteins test
- What kind of taping technique would you recommend?

## Dequervains



## Dequervains

- Measure from IP joint of thumb to mid-shaft portion of ulna. Cut tape in half for a 1" piece. Small slit in end ("Y") for distal anchor. Use 15-25% tension apply distal to proximal. If possible, apply with thumb in flexed position.

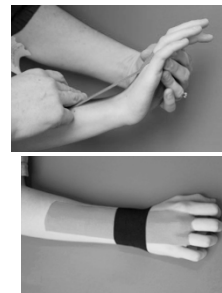

### Case study-wrist sprain

- 16 year old lacrosse player diagnosed with wrist sprain sustained when hyper-flexing wrist during play
- Has had a course of rest and rehab
- Has not returned to quite 100% and wants nonrestrictive support during return to play

### Wrist Sprain

- Measure volar palm to dorsal mid forearm. Cut buttonholes for RF/MF. No tension on distal and proximal anchor/ends in tent position. 25-50% center tape tension. Move pt into flexion to secure middle of tape.
- Measure 2/3 around wrist. Apply dorsal piece 50% tension (mechanical correction) in neutral. Apply ends with wrist extended.



### Case study-mallet finger

- 60 year old male sustained a soft tissue mallet injury while playing in weekend softball game
- Pt did a course of 8 weeks mallet splinting
- Pt has orders to begin AROM and wean splint
- Pt had some compliance issues during splinting phase, but demonstrates full extension with effort when mallet splint removed.
- Healing is considered "fragile"
- Pt wants to return to weekend sports activities and is very active during the week
- Afraid of lag developing if pt moves too fast/aggressively

### Mallet Finger

- Need Two small I strips about 1/2 in in width (one about 4" long, one about 1" long).
- Apply with finger in ext.
- Apply no tension anchor volar distal phal, 50% tension tendon correction over distal and middle phal, paper off tension to no tension rest of finger, no tension on end.
- Apply a second tendon correction 50% tension with small piece. No tension on ends that wrap around finger.



### Case study- CMC OA

- 55 year old female professional flute player diagnosed with CMC OA.
- Has found custom and prefab splinting options to work well for most activities except for flute playing.
- What type of taping would you recommend?

### Moulton, et al, 2001

- Results: 30degrees of MP flexion effectively unloaded the most volar surface of the trapeziometacarpal joint regardless of the presence or severity of arthritic disease present.
- Author's conclusions: In the presence of hyperextension, early intervention to stabilize the MP joint may slow the natural progression of OA at the trapeziometacarpal jt.

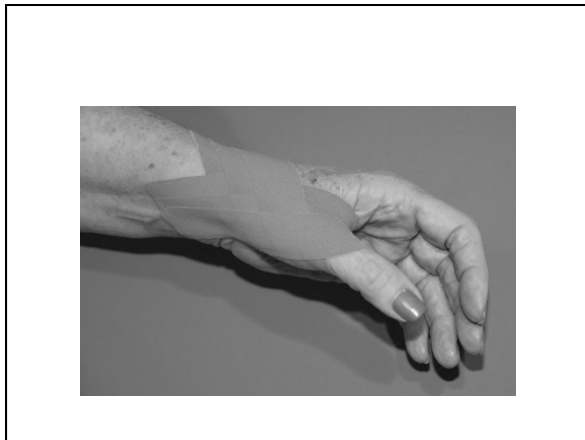### York and Park, 2008

- For CMC OA, the splint or tape should induce palmar abduction, slight flexion and medial rotation which increase natural stability and increase fitting of the joint surfaces.
- The goals: increase stability, reduce pain, decrease inflammation, improve function, reduce mechanical stress that may be causing the instability.

### CMC OA

- Measure distance from dorsal wrist at scaphoid, the going volarly through web and around to volar portion of wrist at scaphoid. Cut 3-1" wide strips at this length.
- Pt positions thumb CMC in 35 deg palmar abd, slight flexion, MP in slight flexion.
- Anchor 1<sup>st</sup> strip at dorsal aspect dist radius. 50% stretch on tape as it is wound around volar aspect of thumb through 1<sup>st</sup> web. End on volar dist.radius. No tension on anchor or end. Repeat with 2<sup>nd</sup> and 3<sup>rd</sup> strips starting more distally to encompass the MP joint.



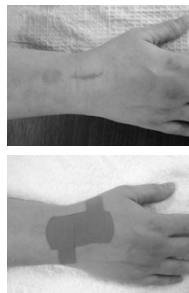


### Case study- scar

- 45 year old female secretary s/p right scaphoid cyst removal with bone graft
- Pt has tried traditional scar management techniques including scar massage and scar pad use
- Pt displeased that scar is pitting and is also restricted with medial/lateral glide
- What type of taping would you use?

### Scar

- Position pt in maximum elongation position. Stretch the middle of an I strip 25-50% and apply on top of scar, no tension on ends.
- For side pieces. Apply anchor with no tension on side you want tissue to move towards, 25-50% tension on tail.



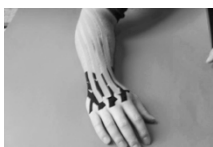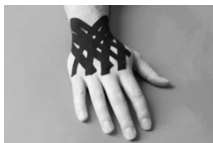### Case study- edema

- 25 year old male construction worker hit in dorsal hand by a board
- X-rays negative for fracture
- Significant dorsal hand swelling noted
- What type of taping would you recommend?



## Edema

- Need 3 fan cut strips (2 about 6", 1 about 8")
- Short pieces-Anchors just proximal to volar distal radius/ulna.
- Long piece anchor lateral elbow
- No tension anchors, 0-15% tension tails, no tension on ends.



## References

- Kaneko S & Takasaki H. Forearm pain diagnosed as intersection syndrome, managed by taping: A case series. JOSTPT. 2011;41:514-519
- Kase, Kenzo, Roek Stockheimer, Kim. Kinesiotaping for Lymphoedema and Chronic Swelling, USA:Kinesio USA,LLC, 2006. Print.
- Kase, Kenzo, Wallis, Jim, Kase,Tsuyoshi, Clinical Therapeutic Applications of the Kinesiotaping Method 2nd edition. Tokyo: Kenzo Kase, 2003. Print
- Kase, Kenzo, Wallis, Jim, Kase, Tsuyoshi, Clinical Therapeutic Applications of the Kinesiotaping Method, 3rd edition. USA, Kinesio IP,LLC, 2013. Print
- KT1,2 and 3 Kinesiotaping Courses, Kinesiotaping Association International, 2014 Phila, Pa. and Baltimore, MD.
- Kinesiology Taping Course 2013, Medical Minds in Motion, Cherry Hill, NJ.

- Lin JJ, Hung CJ, Yang PL. The effects of scapular taping on electromyographic muscle activity and proprioception feedback in healthy shoulders. J Orthop Res. 2011;29:53-57
- Pradeepshankar, Renukadevi M, Gowda N, Punith B, Pai H. Efficacy of kinesiotaping as an adjunct to positional stretching of the coracohumeral ligaments in patients with primary adhesive capsulitis. Innov J Med Health Sci. 2013;3:45 - 51.
- Taylor RL, O'Brien L, Brown T. A scoping review of elastic tape for neck and upper extremity conditions. J Hand Ther. 2014;27:235-246
- Ujino A, Eberman LE, Kahanov I, Renner C, Demchak T. The effects of kinesiotaping and stretching on shoulder ROM. Inter J Athl Ther Train. 2013;March:24-28

**THANK YOU**