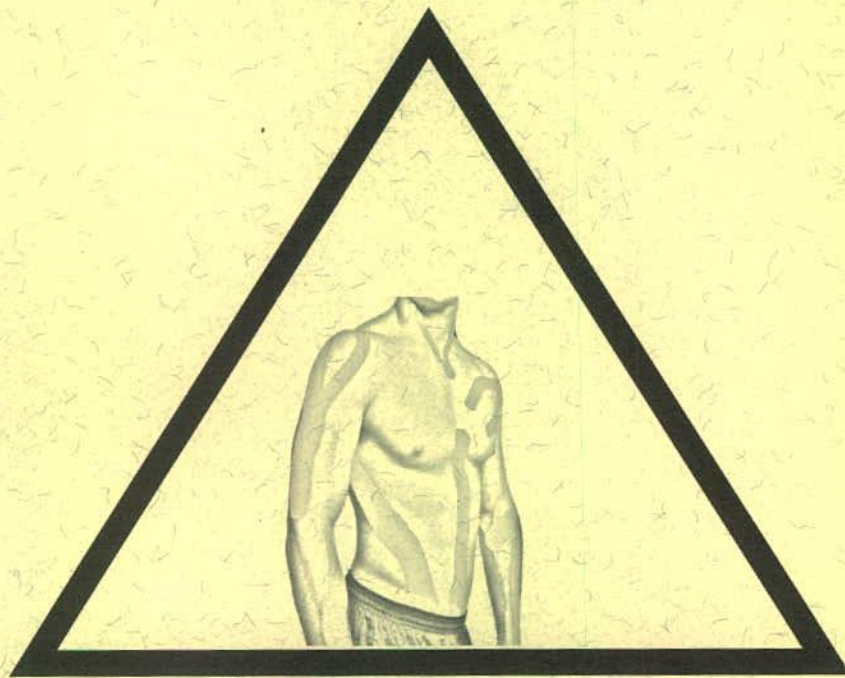


ILLUSTRATED KINESIO TAPING

Fourth Edition

by

KENZO KASE, D.C.



KEN'I-KAI
TOKYO

Copyright and Trademark Information

Copyright© 2003 by Kenzo Kase. All Rights Reserved.

“KINESIO” and “KINESIO TAPING” are registered trademarks® of Ken Ikai, Co. Ltd, Tokyo, Japan. All Rights Reserved.

This book is protected by copyright. No part of this book may be reproduced in any form or by any means, including photocopying, or utilized by any information storage or retrieval system without prior written permission from the copyright owner.

Copyright © 2003 by Kenzo Kase

First Edition October, 1994

Second Edition, January, 1997

Third Edition, December, 1997

Fourth Edition, , 2005

Author Kenzo Kase, D.C.

Edited by Heather Murray, Ph. D, PT, CKTI

The author of this book does not dispense medical advise nor prescribe the use of these Kinesio Taping® method as a form of treatment for medical problems with the advice of a physician, either directly or indirectly. The intent of the author is only to offer information of a general nature to help you cooperate with your doctor in your mutual quest for health. In the event you use any of the information in this book for yourself, you are prescribing for yourself, which is your constitutional right, but the author and publisher assume no responsibility for your actions.

Publisher: KEN'I KAI INFORMATION

ISBN 1-880047-24-1

TABLE OF CONTENTS

INTRODUCTION

Kinesio Taping	6-12
----------------------	------

SHOULDER GIRDLE

Deltoid.	14-15
Teres major	16-17
Pectoralis major	18-19
Teres minor	20-21
Rhomboid major	22-23
Rhomboid minor	24-25
Triceps brachii.	26-27
Biceps brachii	28-29
Brachioradialis	30-31
Supinator.	32-33
Pronator teres	34-35
Pronator quadratus	36-37
Palmaris longus.	38-39
Extensor pollicis longus	40-41
Extensor digiti brevis	42-43
Brachial plexus tape	44-45

TABLE OF CONTENTS

TRUNK

Scalenus anterior	50-51
Scalenus posterior	52-53
Sternocleidomastoid	54-55
Longus capiti, Longus colli, Sternohyoideus, Thyreohyoideus	56-57
Latissimus dorsi	58-59
Upper Trapezius	60-61
Middle Trapezius	62-63
Lower Trapezius	64-65
Rectus abdominis	66-67
External abdominis oblique	68-69
Internal abdominis oblique	70-71
Diaphragm anterior	72-73
Diaphragm posterior	74-75
Erector spinae	76-77
Postvertbral muscles	78-79

PELVIC GIRDLE

Gluteus maximus	80-81
Gluteus medius & minimus	82-83
Tensor fascia lata	84-85
Sartorius	86-87
Adductors	88-89
Piriformis	90-91
Quadriceps femoris	92-93
Hamstrings	94-95
Soleus & Gastrocnemius	96-97
Extensor hallucis longus	98-99
Peroneus longus and Brevis	100-101
Flexor hallucis brevis	102-103
Sciatic nerve tape	104-107

AUTHOR'S PROFILE	109
------------------------	-----

Introduction

History of Kinesio Taping®

Kinesio Taping® is a modality treatment based on the body's own natural healing process. The Kinesio Taping method exhibits its efficacy through the activation of the neurological and circulatory systems. This method basically stems from the science of Kinesiology, recognizing the importance of body and muscle movement in rehabilitation and everyday life. Hence the name "Kinesio" is used. Muscles attribute not only to the movements of the body, but also controls the circulation of venous and lymph flows, body temperature, etc. Therefore, the failure of the muscles to function properly induces various kinds of health maladies.

Consequently, so much attention was given to the importance of muscle function that the idea of treating the muscles in order to activate the body's own healing process came about. Using an elastic tape, it was discovered that muscles and other tissues could be helped by outside assistance. Employment of Kinesio Taping creates a totally new approach to treating nerves, muscles, and organs. The first application of Kinesio Taping was for a patient with articular disorders.

For the first 10 years, orthopedists, chiropractors, acupuncturists and other medical practitioners were the main users of Kinesio Taping. Soon thereafter, Kinesio Taping was discovered by Olympic volleyball players for preventative maintenance in Japan and word quickly spread to other athletes. Today, Kinesio Taping is accepted by medical practitioners and athletes in Japan, the United States, Europe, South America, Australia and other Asian countries as well.

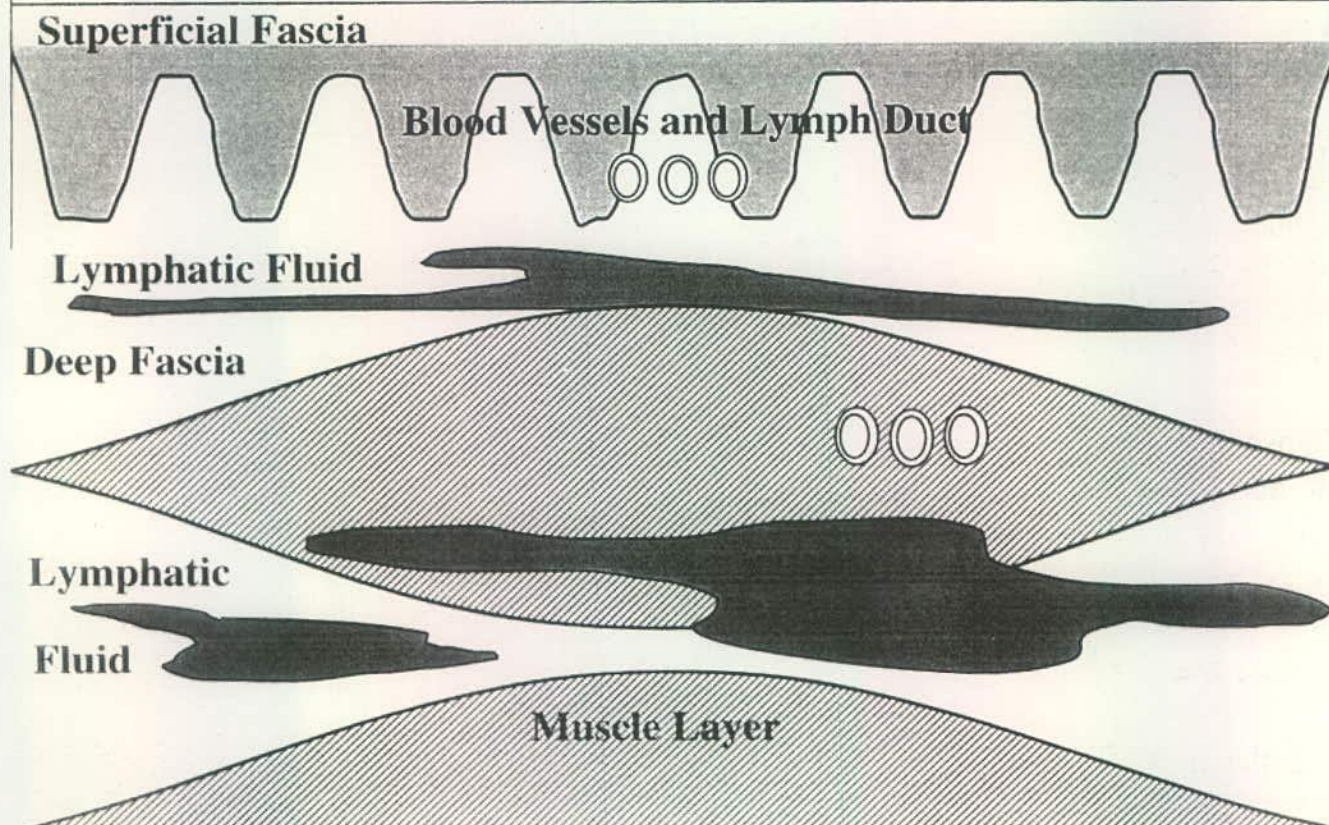
Muscle Function, Inflammation & Pain

Muscles constantly extend and contract within a normal range; however, when muscles over-extend and over-contract, such as when lifting an excessive amount of weight, muscles cannot recover and become inflamed. When a muscle is inflamed, swollen or stiff due to fatigue, the space between the skin and muscle is compressed, resulting in constriction to the flow of lymphatic fluid. This compression also applies pressure to the pain receptors beneath the skin, which in turn communicates "discomfort signals" to the brain- the person experiences PAIN. This type of pain is known as myalgia, or muscular pain.

Illustrated Kinesio Taping® Introduction

Space Flow of Lymphatic Fluid

Skin and Neural Receptors



Kinesio Taping® is FUNDAMENTALLY Different from Conventional Sports Taping

Conventional athletic tape is designed to constrict and immobilize movement of affected muscles and joints. For this purpose, several layers of tape must be rolled around and/or over the afflicted area, applying significant pressure; resulting in the obstruction of the flow of bodily fluids-- an UNDESIRABLE side-effect. This is also the reason athletic tape is generally applied immediately before the sports activity, and removed immediately after the activity is finished. On the other hand, Kinesio Taping is based on a different philosophy that aims to give free range of motion in order to allow the body's muscular system to heal itself bio-mechanically. To ensure that the muscles have free range of motion, elastic tapes with an elasticity of 130-140 % of its original length are recommended for Kinesio Taping. This specific elasticity also will not allow an over stretch of the muscles themselves. It may look like regular athletic tape, but Kinesio Tex Tape and Kinesio Taping are fundamentally different than athletic tape.

Illustrated Kinesio Taping® Introduction

Four Major Functions of Kinesio Taping®

Four major functions of Kinesio Taping have been observed in practice and in the laboratory. What you may reasonably expect from Kinesio Taping are as follows:

1. Supports Muscle:

- Improves muscle contraction in weakened muscle;
- Reduces muscle fatigue;
- Reduces over-extension and over-contraction of muscle;
- Reduces cramping and possible injury to muscle;
- Increases ROM (Range of Motion); and
- Relieves Pain

2. Removes Congestion to the Flow of Body Fluids:

- Improves blood and lymphatic circulation;
- Reduces excess heat and chemical substances in tissue;
- Reduces inflammation; and
- Reduces abnormal feeling and pain in skin and muscle.

3. Activates Endogenous Analgesic System:

- Possibly activates spinal inhibitory system; and
- Possibly activates descending inhibitory system.

4. Corrects Joint Problems:

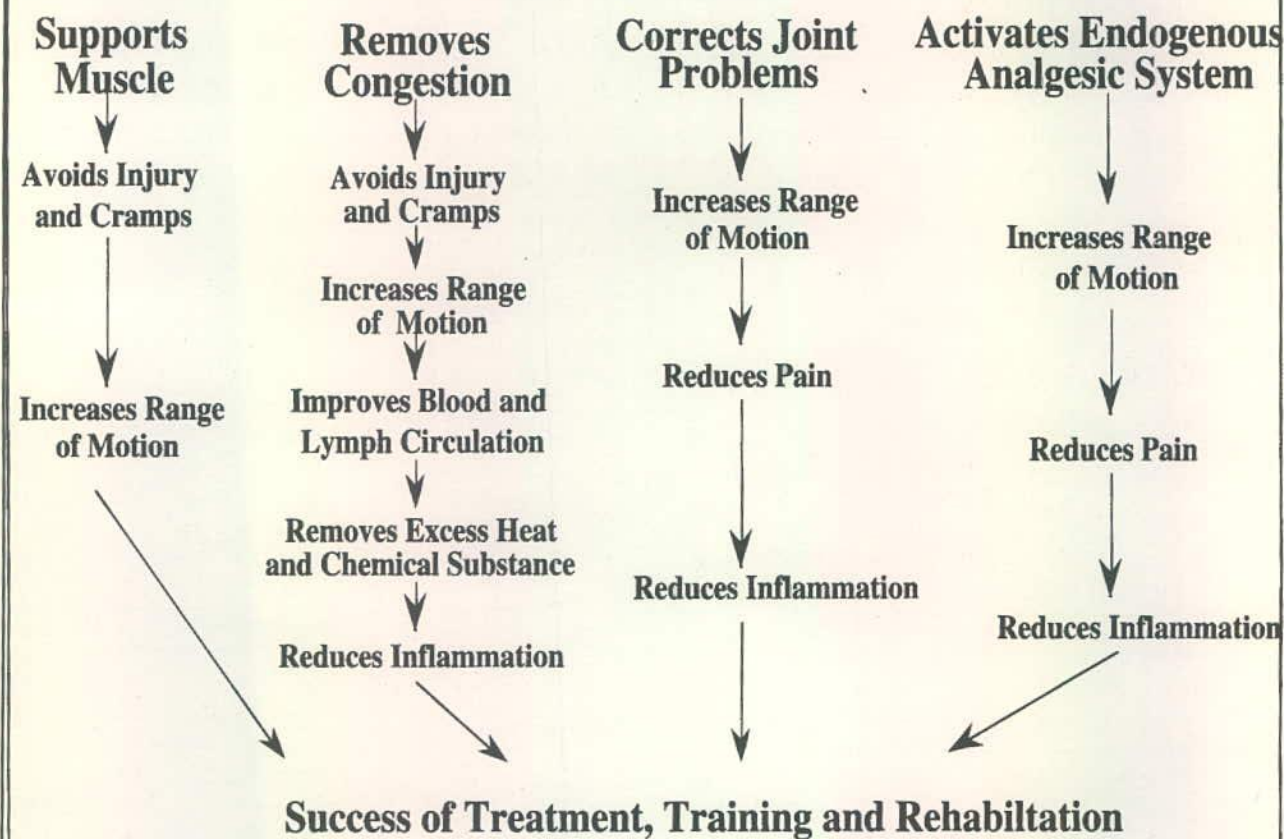
- Adjusts misalignment caused by spasm and shortened muscle;
- Normalizes muscle tone and abnormality of fascia in joints;
- Improves ROM; and
- Relieves pain.

Illustrated Kinesio Taping® Introduction

How Kinesio Taping Works

Apply Tape on Skin

4 Major Functions

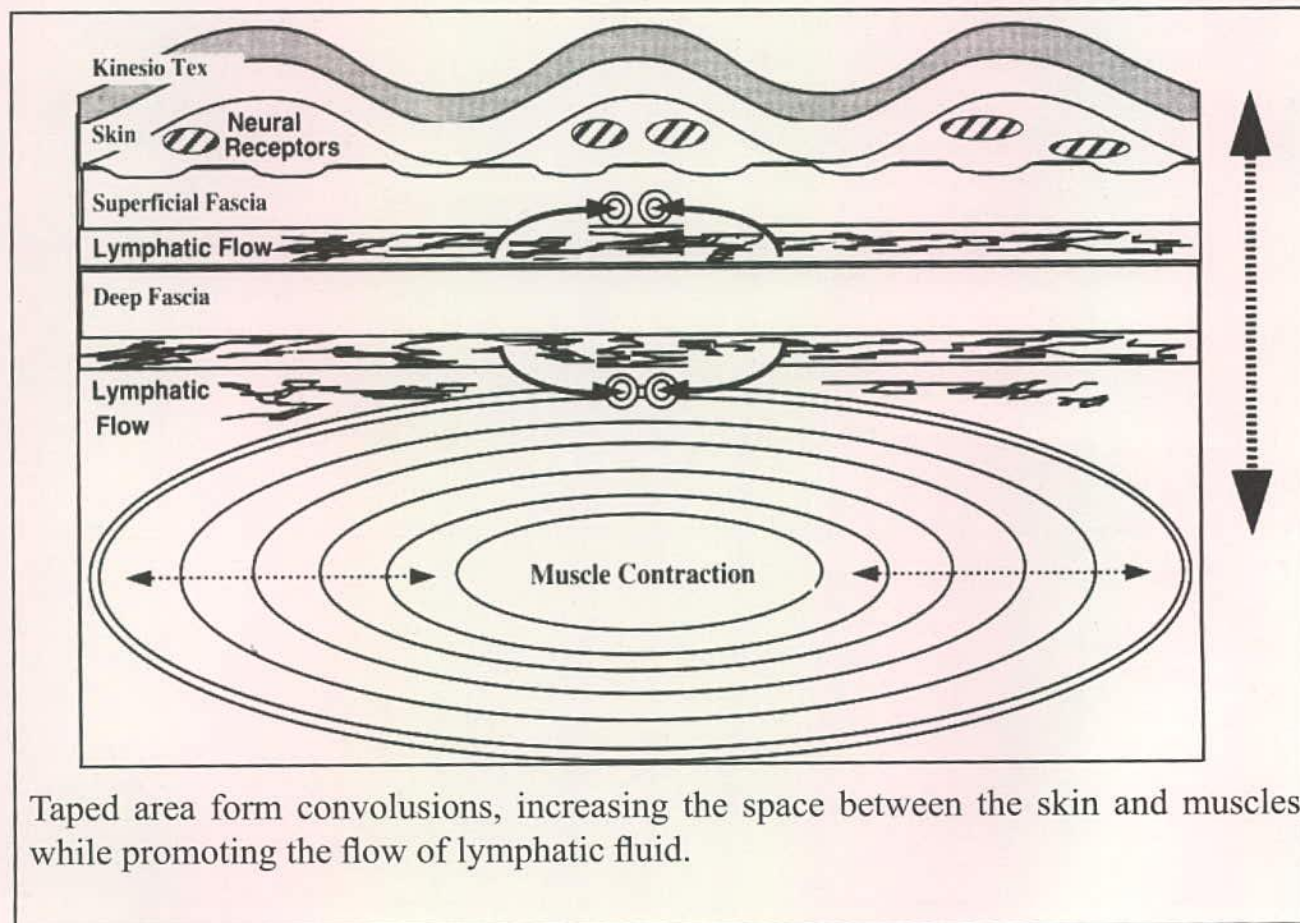


Illustrated Kinesio Taping® Introduction

How to Apply Kinesio Taping® Technique?

To Stretch or NOT to Stretch.....?

As stated before, a recommended elasticity of tape for this technique is from 130-140% of its original length. An important point to remember is that for over-used or acutely damaged muscle, the tape is applied **with NO TENSION**, and from the **INSERTION TO ORIGIN** of the muscle. Using the preferred elastic tape "KINESIO® TEX TAPE", would indicate simply applying the tape by taking it off the paper backing while applying the technique with no extra tension. This alone represents a total elastic stretch of 5-10% of the preferred tape. In this case, stretch the skin of the affected area before application of the tape. This is done by stretching the muscles and joints in the affected area. After application, the taped skin will form convolutions when the skin and muscles contract back to their normal position. When the skin is lifted by this technique, the flow of blood and lymphatic fluid beneath the skin improves. Also the additional proprioceptive stimulation of the application working in the opposite direction of the muscle contraction assists to relax the overused muscle.



Illustrated Kinesio Taping® Introduction

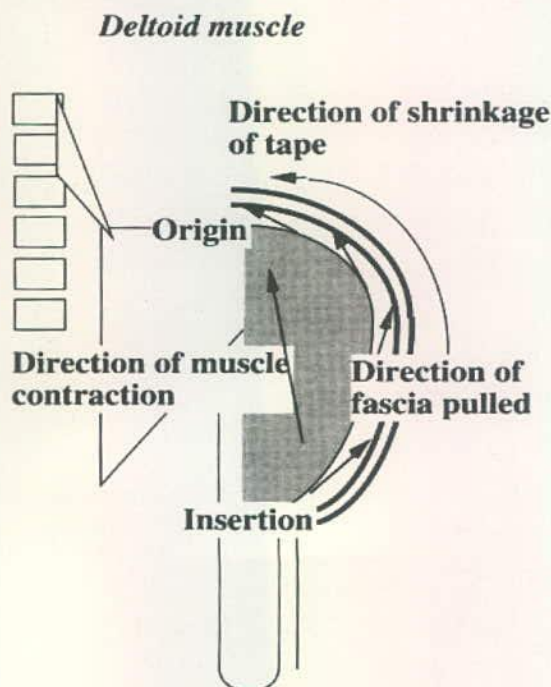
For chronic or acutely weak muscles, where support with full range of motion is desired, the tape is applied from the **ORIGIN TO INSERTION** of the muscle. To accomplish this, the area, joint, or muscle is placed in an elongated position as before, but **LIGHT TENSION** (approx. 15%) is now used to give more stimulation and to support the contraction of the muscle during use.

In the case where joints or ligaments are injured, the tape should be applied with medium to full **STRETCH**, while maintaining a functional joint position during application. The damaged joints or ligaments are incapable of functioning normally and rely on stretched tape for correction and assistance. It is also important to note that while depending on the injury, tape is either stretched or not stretched. This does not mean that the actual application technique will change.

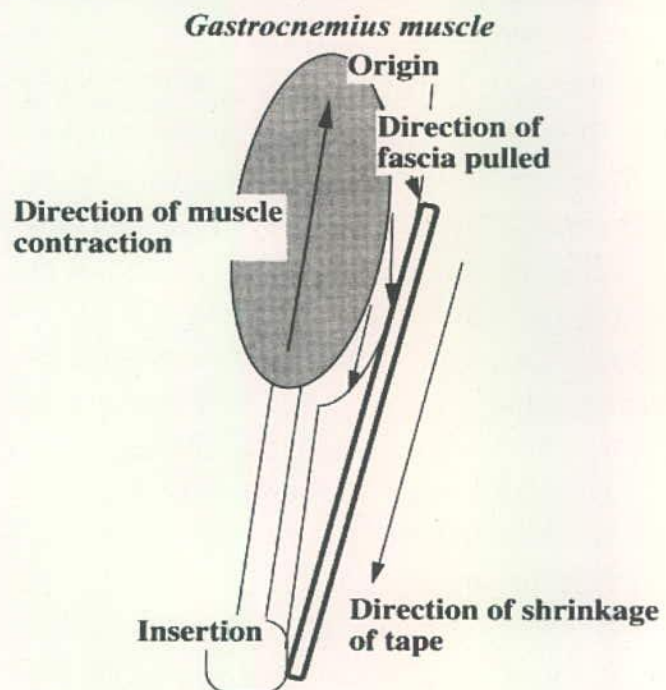
The incredible effect on pain can be attributed to the lifting effect and Gate Control Theory.

Principles of Kinesio Taping in Application

To treat a weakened muscle, apply tape from origin to insertion.



To prevent cramping or over-contraction of a muscle, apply tape from insertion to origin.



Illustrated Kinesio Taping® Introduction

Tape Around the Muscle

Tape can be applied as a single strip "I", or in the shapes of an "X" or "Y", depending on the shape and size of the targeted muscles. The basic principle of therapeutic taping for weakened muscle is to wrap the tape around the affected muscle. Start from where the muscle begins (ORIGIN) and continue along the muscle, and finish where the muscle ends (INSERTION). For preventing cramping or over-contraction (overuse of muscles), tape should be applied from insertion to origin.

If you are treating yourself without assistance, it is important to remember the basic principle of stretching the skin before application, no matter where the pain is located. For example, if the side of the forearm is the source of the pain, you should bend your hand back before applying the tape. Similarly, if the source of pain is the outside of the forearm, then the wrist should be bend forward. This principle must be strictly observed. For treatment of muscle pain, Kinesio Taping is ineffective unless the skin is stretched.

Skin Preparation

The skin should be clear and free of oils and lotions prior to tape application. Anything that limits the acrylic adhesive ability to adhere to the skin will limit both effectiveness and length of application.

For a limited number of patients body hair may limit adhesion. If the degree of body hair limits adhesion then the practitioner may need to shave or clip the area to be treated. If applying tape in an area of moisture, the water resistant product may be preferable.

Removal of Tape from Paper Backing

To smoothly remove the paper backing, hold the tape vertically and place your index finger on the top edge of the tape. Then by rolling, simply roll back your index finger downwards to peel the tape from its backing. Any contact with the acrylic adhesive will diminish its adhesive abilities. Try not to touch the adhesive as much as possible.

When removing the Kinesio Tex Tape from the paper backing, only remove the amount required to begin the base application. Once base application is completed, the practitioner may want to peel the remaining paper backing away. When doing this, remember that 10% stretch is applied to the tape during manufacturing.

Two common methods are used to remove the tape from the paper backing. One, tear paper backing just prior the base of the Y-cut, leaving the paper backing on the tails. As each tail is applied, the Kinesio Tex Tape can be removed from the paper substrate using the paper off tension (25%). Two, remove the paper backing from the tails and lightly have the Kinesio Tex Tape come into contact with the skin. Do not rub the Kinesio Tex Tape as this will initiate glue adhesion. As the Kinesio Tex Tape contacts the skin, it will grab the skin and be held in place.

SHOULDER GIRDLE

Deltoid

Teres major

Pectoralis major

Teres minor

Rhomboid major

Rhomboid minor

Triceps brachii

Biceps brachii

Brachio radialis

Supinator

Pronator teres

Pronator quadratus

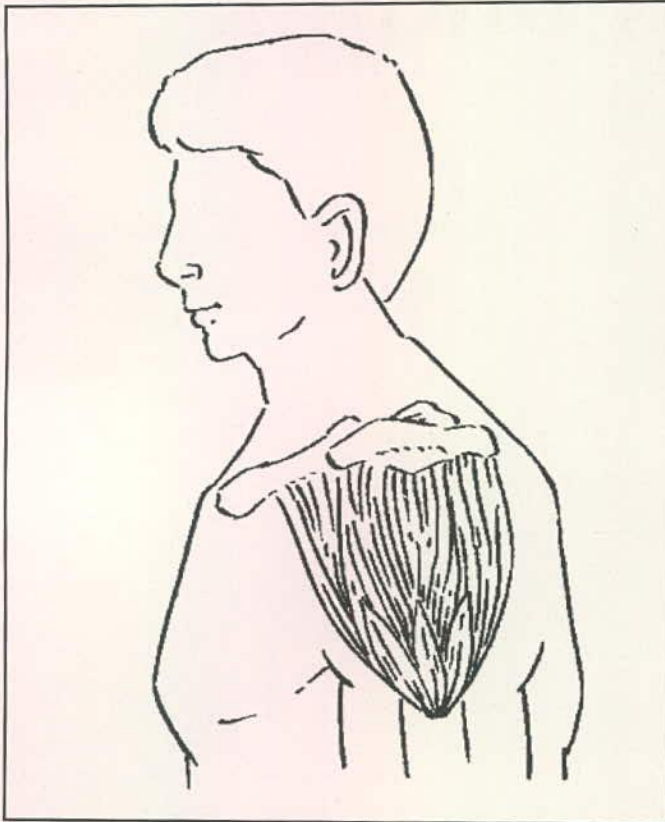Palmaris longus

Extensor pollicis longus

Extensor digiti brevis

Brachial plexus (nerve) tape

DELTOID



ORIGIN

ANTERIOR FIBERS:

The anterior border and upper surface of the lateral 1/3 (third) of the clavicle.

MIDDLE FIBERS:

Lateral border and upper surface of the acromion process.

POSTERIOR FIBERS:

Posterior border of the spine of the scapula.

INSERTION

Deltoid tuberosity of humerus; sensitive area about half way down arm bone.

NERVE C5, C6,

Axillary Nerve

FUNCTION

The deltoid muscle is the major abductor of the humerus, composed of anterior, middle and posterior fibers.

The anterior fibers cause flexion and internal rotation, the middle fibers give rise to abduction and the posterior fibers cause extension and external rotation. When the entire muscle contracts, the result is abduction of the arm.

Arm abduction is difficult when the deltoid becomes weakened either by injury to C5-C6 spinal nerve roots or to the axillary nerve. Also, bronchitis, pleurisy, influenza or other conditions affecting the lungs may have an influence on the deltoid muscle.

TAPE SPECIFICATIONS

WIDTH 2 in.

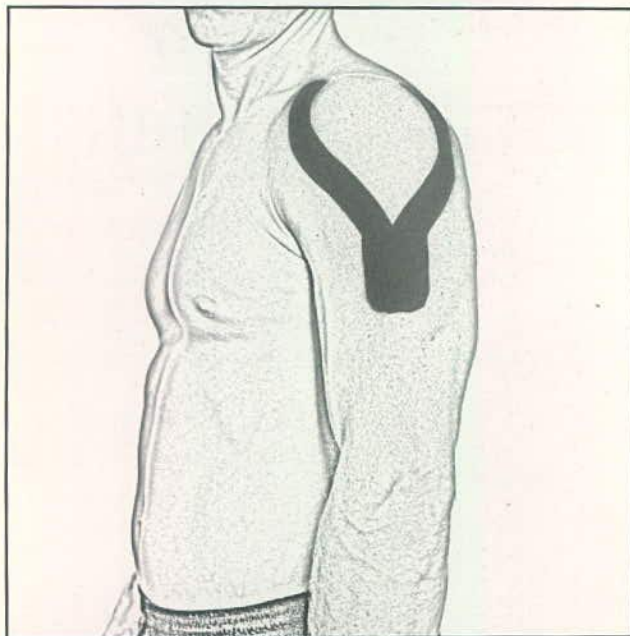
LENGTH 8 in.

Y-SHAPED TAPE

CLINICAL APPLICATION

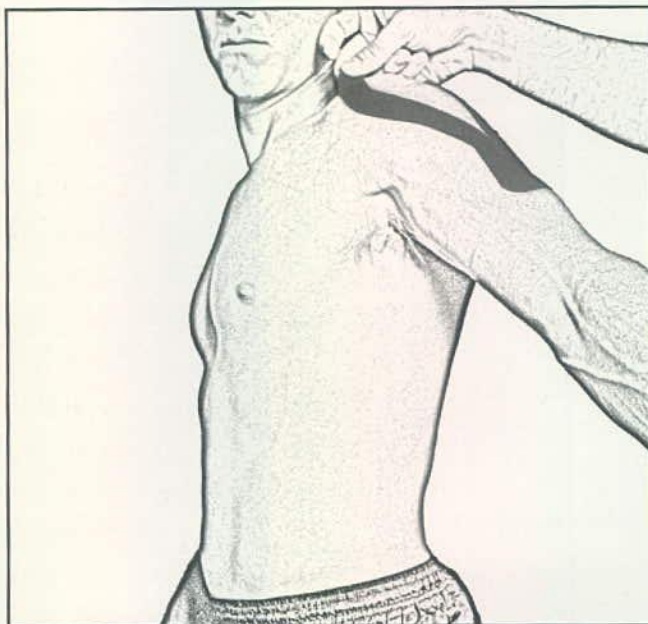
- Chronic shoulder dislocation.
- Acromio-Clavicular dislocation.

COMPLETED TAPING

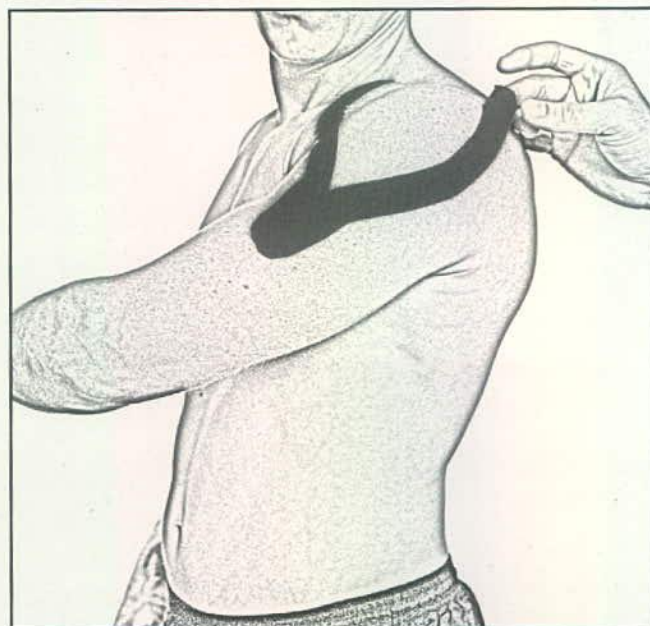


With shoulder lowered and arm in relaxed position.

HOW TO ADHERE

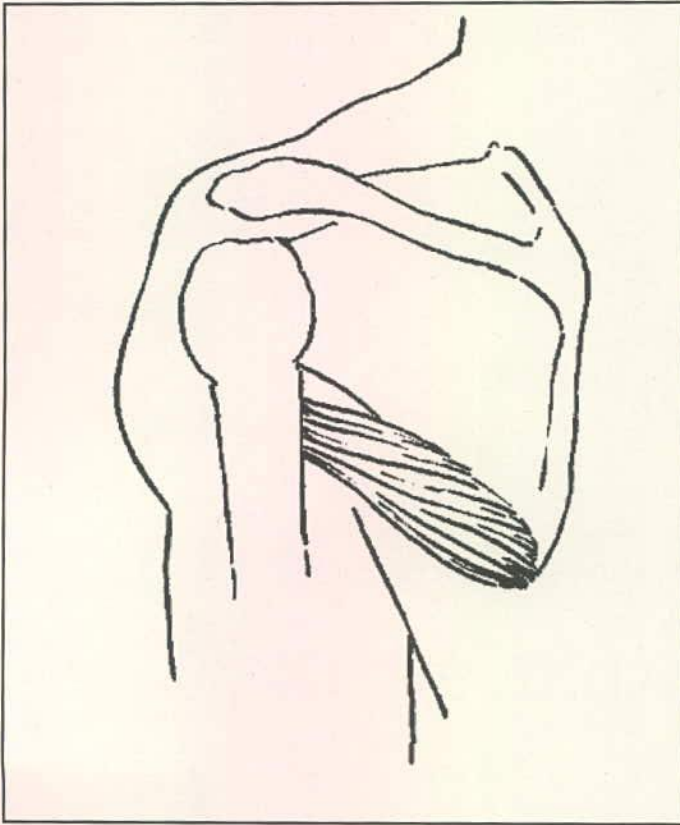

Using a "Y" tape, adhere base of "Y" to insertion of deltoid muscle. Abduct shoulder and apply tape to anterior fibers of the deltoid.



Next, internally rotate and adduct shoulder to touch Thumb to opposite shoulder.

TERES MAJOR



ORIGIN

Posterior surface of inferior angle of scapula.

INSERTION

Medial border of bicipital groove of humerus.

NERVE C6, C7

Lower subscapular nerve

FUNCTION

Adduction and internal rotation of arm. Chronic contraction of teres major may result in altered scapulohumeral rhythm where the scapula is pulled from its normal position as the arm is raised. This condition is often noted in cases of "frozen shoulder". Application of Kinesio Taping to the skin over the teres major has been noted to decrease pain and improve shoulder flexion and abduction. The activities of pushing, throwing and hitting are strongly influenced by teres major.

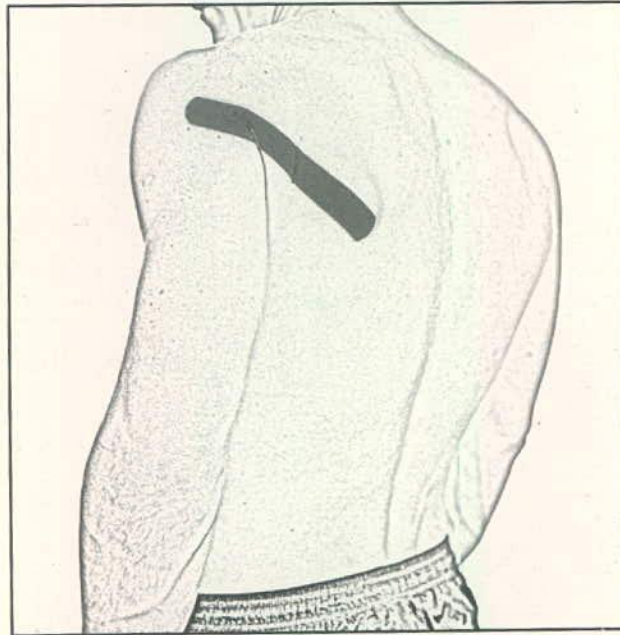
TAPE SPECIFICATIONS

WIDTH 1 in.
LENGTH 6 in.
I-SHAPED TAPE

CLINICAL APPLICATION

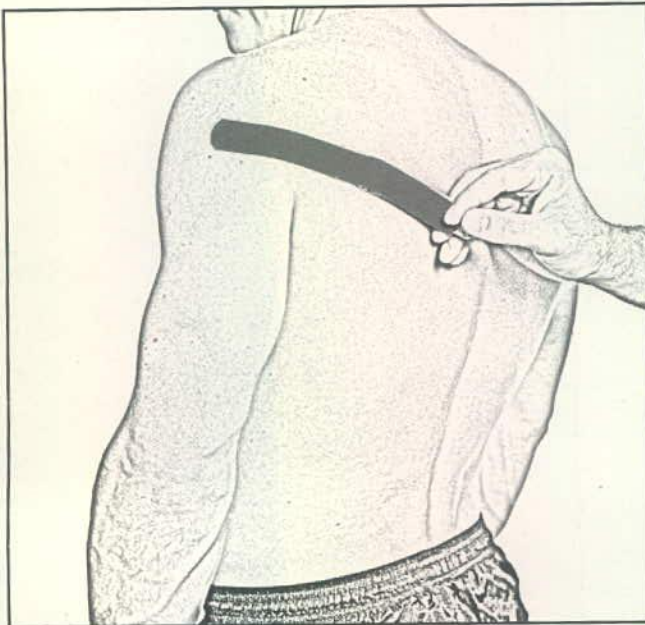
- Frozen shoulder
- Shoulder pain aggravated by golf, tennis or baseball.

COMPLETED TAPING

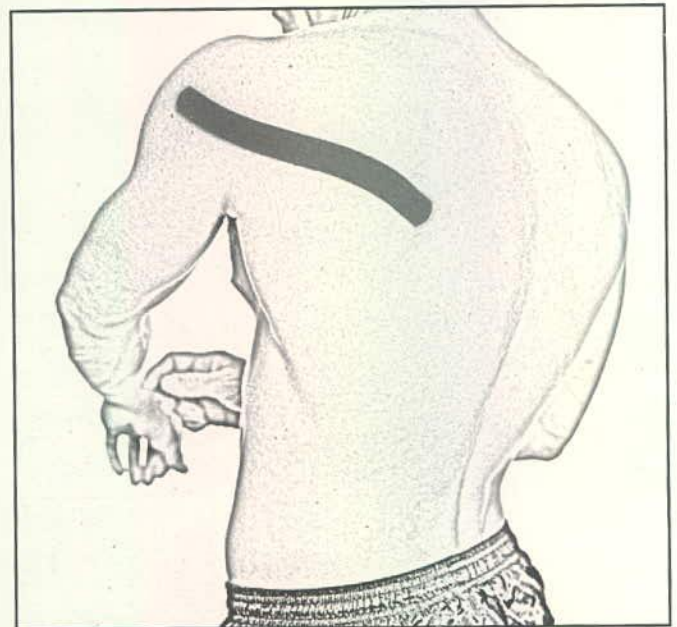


Teres major tape when arm is in relaxed position.

HOW TO ADHERE

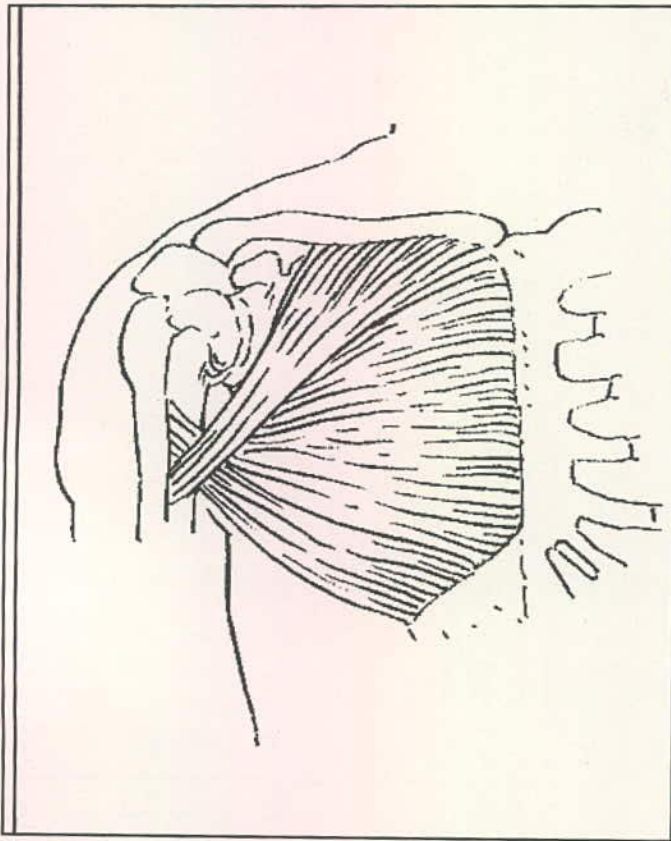


Flex elbow slightly and abduct arm to about 45° . In this position, affix tape gently to origin and insertion of teres major.



Abduct arm to 90° and move arm into horizontal adduction. At point where teres major is at maximum stretch, completely adhere tape.

PECTORALIS MAJOR



ORIGIN

Clavicular Head:

Anterior surface of medial half of clavicle.

Sternocostal Head:

Anterior surface of sternum, superior six costal cartilages, and aponeurosis of external abdominal oblique muscle.

INSERTION

Crest of bicipital groove of humerus.

NERVE C5 - C8, T1

Medial and Lateral pectoral nerves

FUNCTION

Pectoralis major acts to adduct and internally rotate the humerus. It has two heads: clavicular and sternocostal. The Clavicular head, acting with the anterior deltoid, flexes and adducts the arm; the sternocostal head adducts the arm and extends arm from a flexed position.

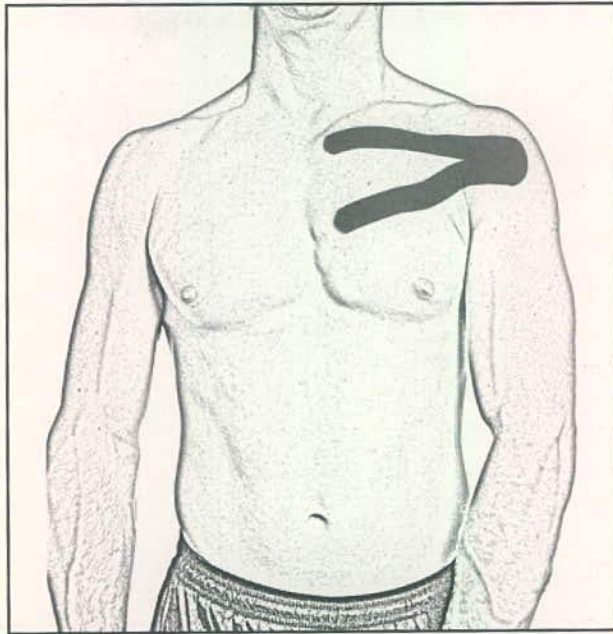
TAPE SPECIFICATIONS

WIDTH 2 in.
LENGTH 6-7 in.
Y-SHAPED TAPE

CLINICAL APPLICATION

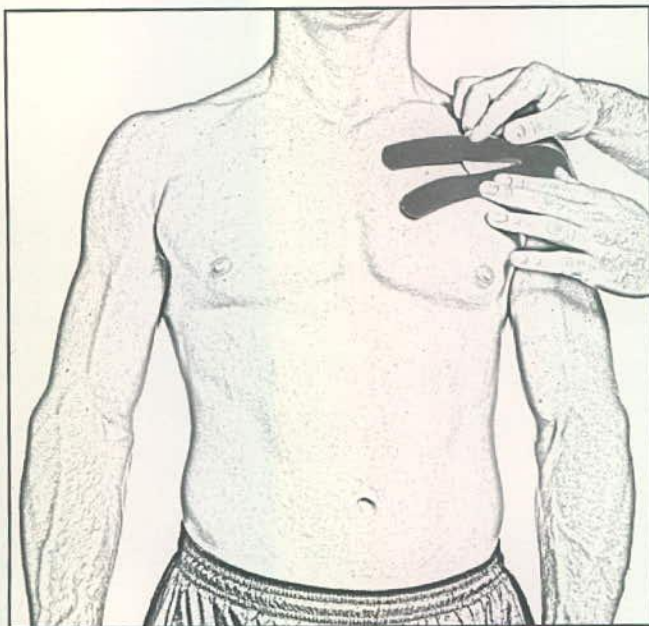
- Shoulder girdle complaints, pain in the hand, Parathesis (numbness), Bronchitis, Asthma, Chest pain.

COMPLETED TAPING

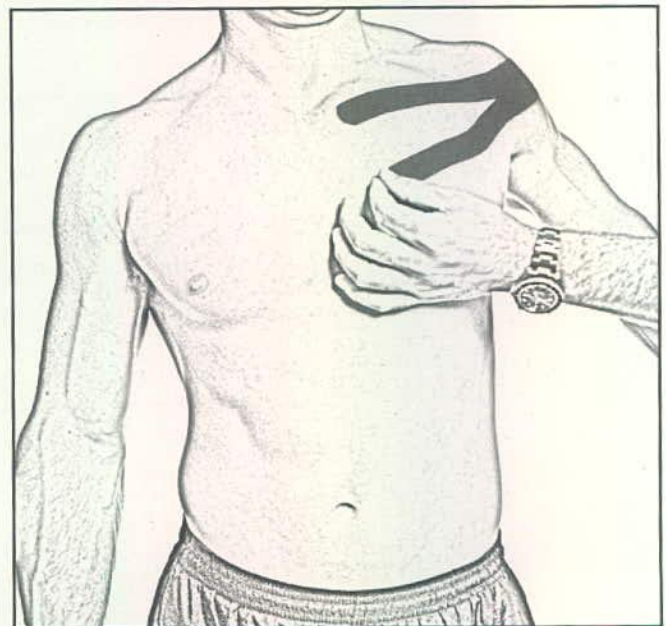


Pectoralis Major Tape when arm is in relaxed position.

HOW TO ADHERE

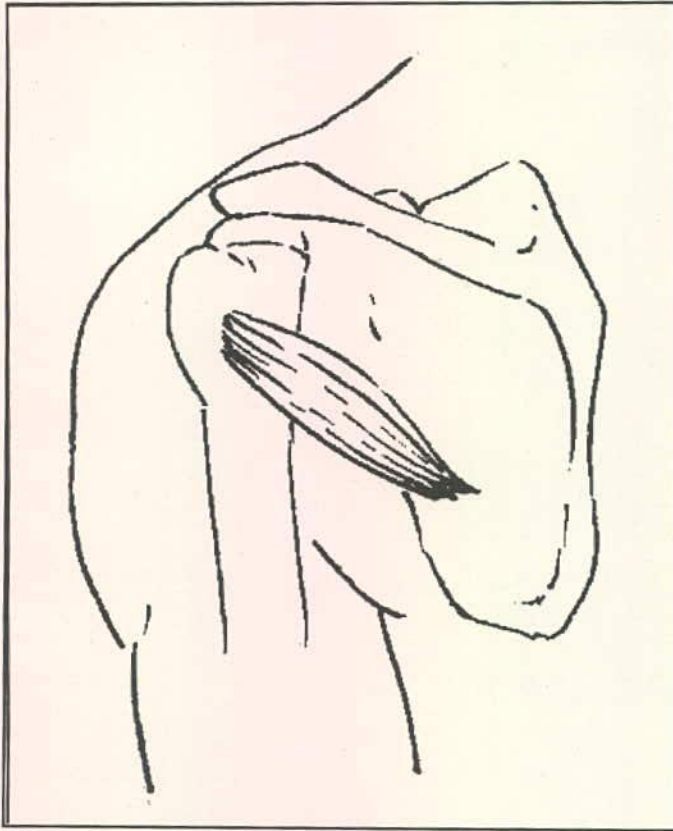


Externally rotate shoulder and apply the Y-base to region of bicipital groove.



With shoulder in external rotation, extend arm to adhere tape tails to surround clavicular and sternocostal heads.

TERES MINOR



ORIGIN

Superior part of lateral border of scapula.

INSERTION

Lower facet of greater tuberosity of humerus.

NERVE C5 - C6

Axillary Nerve

FUNCTION

In association with the infraspinatus muscle, teres minor externally rotates arm; with infraspinatus and subscapularis helps to hold humeral head in glenoid cavity of scapula. Weakness of teres minor may cause luxation of the shoulder, noted often in baseball players. Atrophy of the muscle may be associated with axillary nerve injury.

TAPE SPECIFICATIONS

WIDTH 1 in.

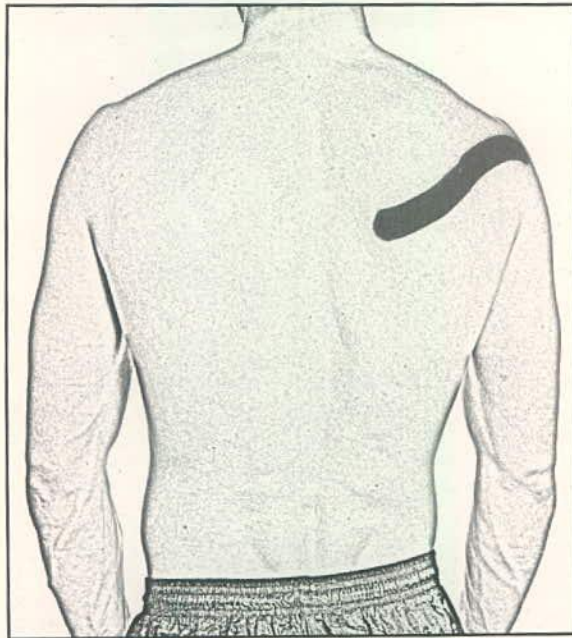
LENGTH 4 in.

I-SHAPED TAPE

CLINICAL APPLICATION

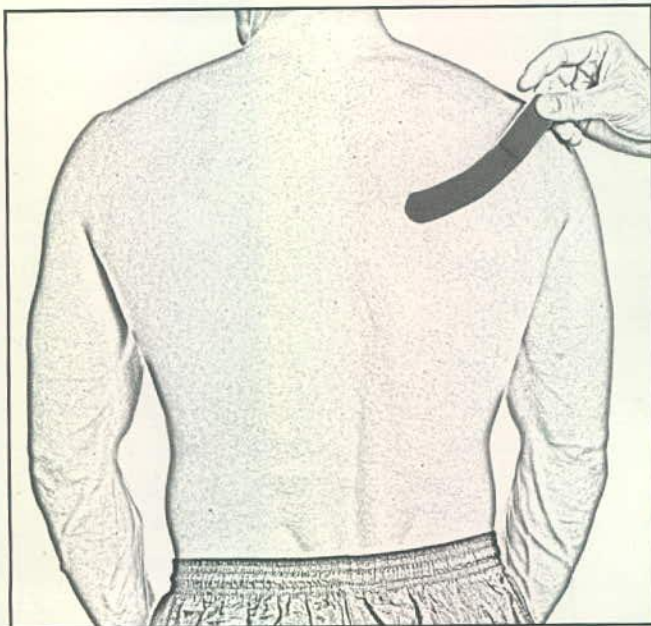
- Frozen shoulder
- Brachial neuralgia

COMPLETED TAPING

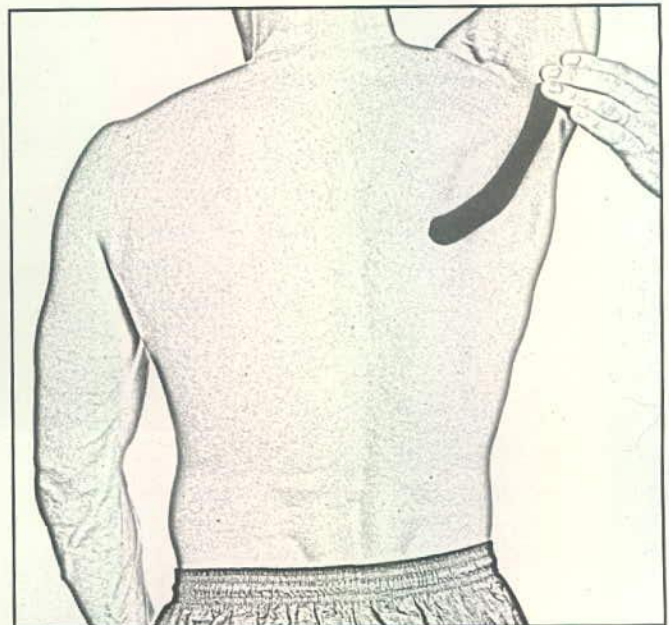


Teres minor tape when arm is in relaxed position.

HOW TO ADHERE

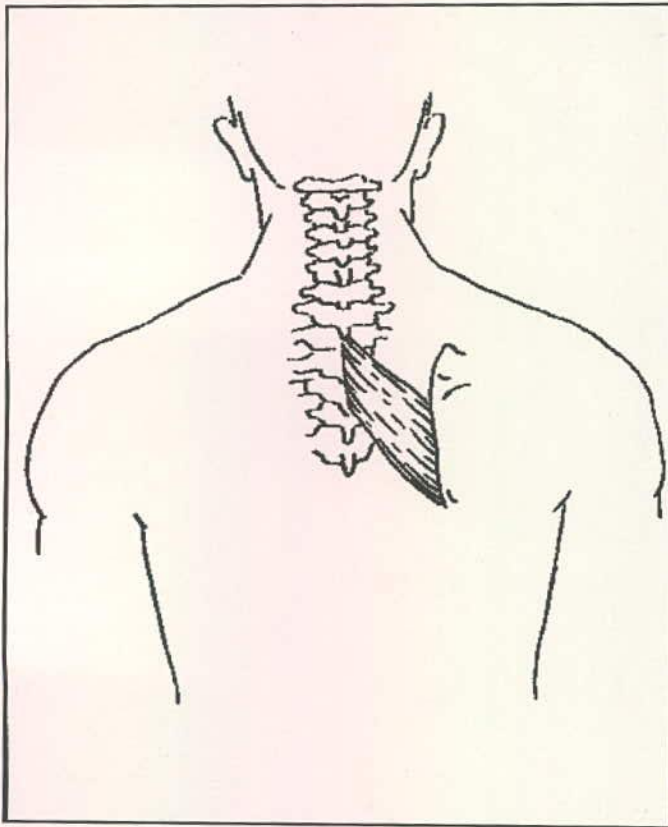


Abduct arm to slightly and extend elbow. Affix the ends of the tape to the origin and insertion regions of teres minor.



Next, abduct the arm to 90°, flex elbow and internally rotate shoulder. Touch thumb to opposite shoulder and adhere the tape to the patient.

RHOMBOID MAJOR



ORIGIN

Rhomboid Major:
Spinous process of T2-T5 vertebrae

INSERTION

Medial border of scapula from level of spine to inferior angle.

NERVE C4 - C5

Dorsal scapular nerve.

FUNCTION

Retract or adduct scapula and rotate glenoid cavity downward; fix scapula to thoracic wall. In conjunction with pectoralis minor, it helps with maintaining correct posture. When poor posture is present, it influences both pectoralis minor and serratus anterior, as well as allowing the scapula to protract to encourage rounded shoulders and forward head.

Referred pain associated with inflammation of the liver or gall bladder may be found in the posterior thoracic wall in the region of the rhomboid muscle. It may also be found in the anterior chest region; this might affect the sternocostal portion of the pectoralis major muscle.

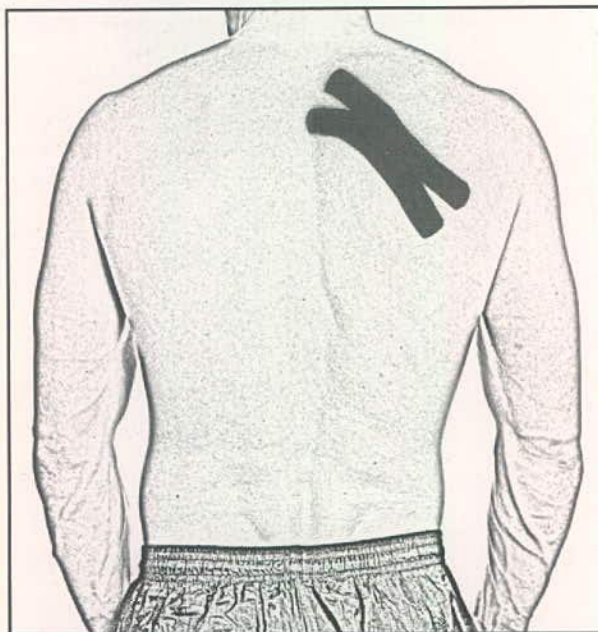
TAPE SPECIFICATIONS

WIDTH 2 in.
LENGTH 5 in.
X-SHAPED TAPE

CLINICAL APPLICATION

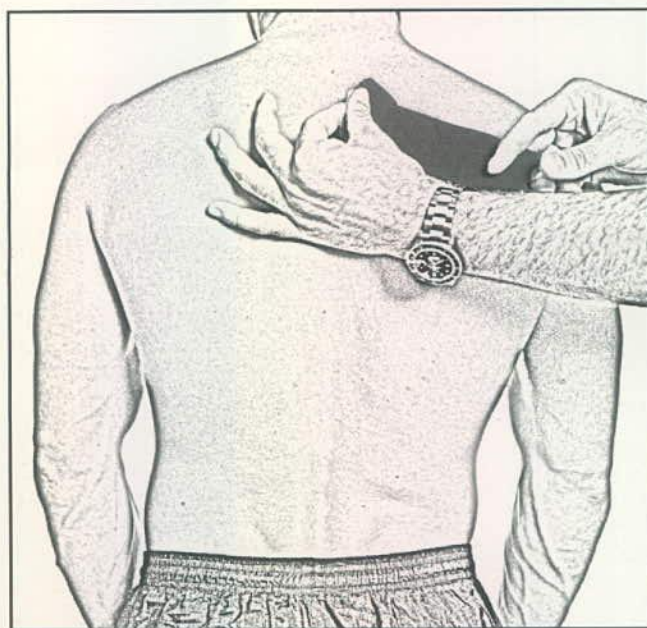
- Scapulae Pain.
- Rib subluxation.
- Stiff shoulder.

COMPLETED TAPING

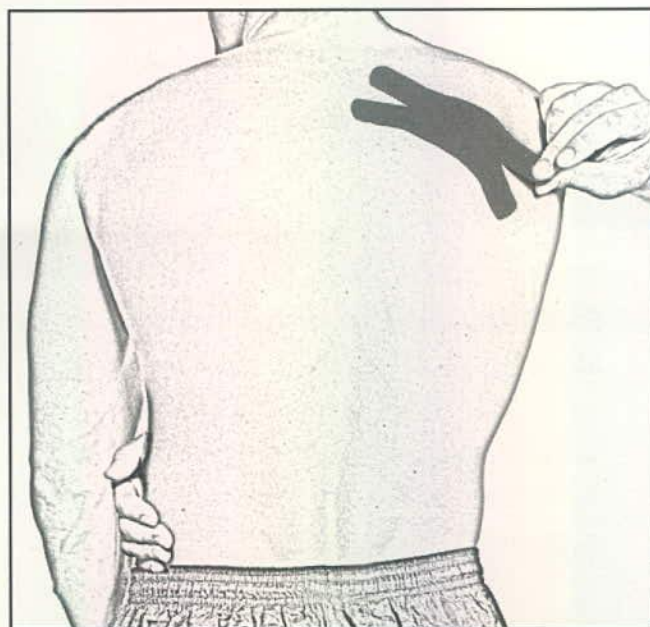


Rhomboid major tape in relaxed position.

HOW TO ADHERE

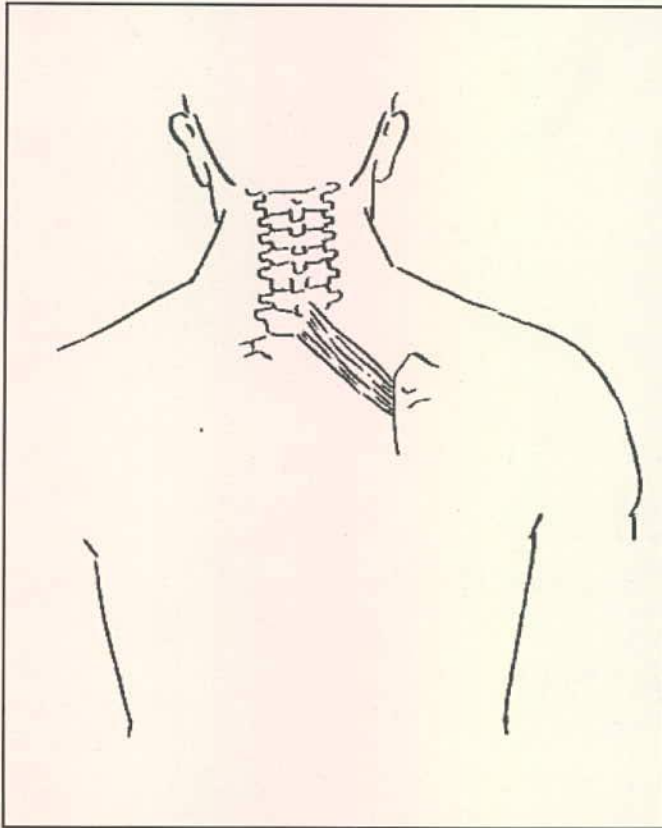


Patient extends upper arm somewhat and extends shoulder backwards, in order to clearly distinguish scapula. Holding both ends of "X" tape, adhere it over the belly of rhomboid major.



Next, patient's arm is horizontally adducted across front of body with internal rotation so as to reach thumb toward their other hip. When the scapula is in a protracted and slightly downward position, adhere the tape. Apply tape tails with no stretch.

RHOMBOID MINOR



ORIGIN

Nuchal ligament and spinous process of C7-T1 vertebrae.

INSERTION

Medial border of scapula at level of scapular spine.

NERVE C4 - C5

Dorsal scapular nerve.

FUNCTION

Retract or adduct scapula and rotate glenoid cavity downward; fix scapula to thoracic wall. In conjunction with pectoralis minor, it helps with maintaining correct posture. When poor posture is present, it influences both pectoralis minor and serratus anterior, as well as allowing the scapula to protract to encourage rounded shoulders and forward head.

Referred pain associated with inflammation of the liver or gall bladder may be found in the posterior thoracic wall in the region of the rhomboid muscle. It may also be found in the anterior chest region; this might affect the sternocostal portion of the pectoralis major muscle.

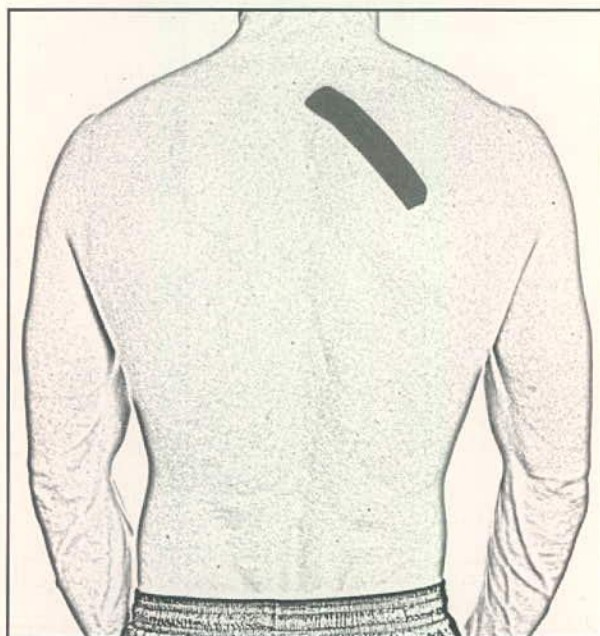
TAPE SPECIFICATIONS

WIDTH 1 in.
LENGTH 4 in.
I-SHAPED TAPE

CLINICAL APPLICATION

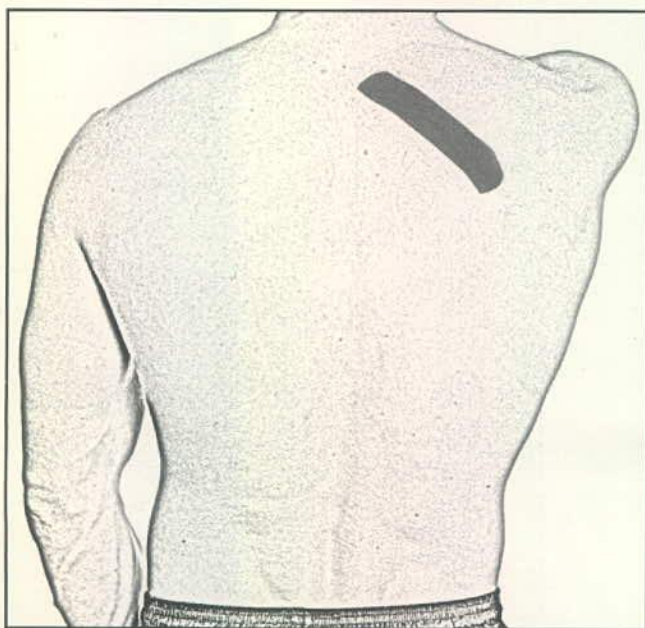
- Pain between upper section of Scapulas.
- Stiff shoulder.

COMPLETED TAPING

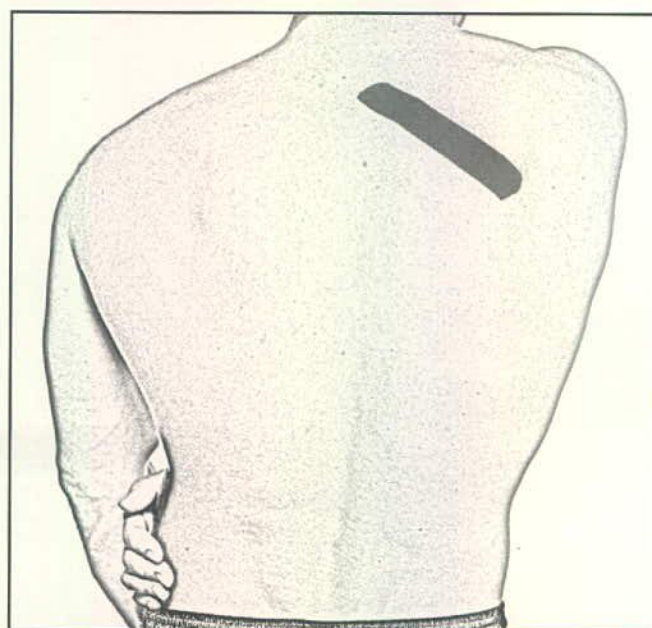


Rhomboid Minor tape in relaxed position.

HOW TO ADHERE

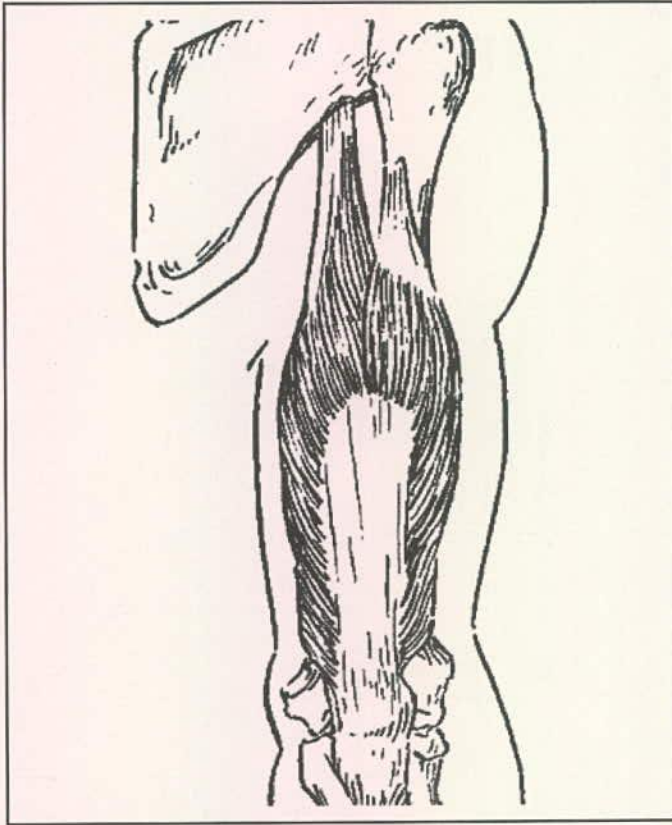

Flex elbow to 90° and abduct arm to shoulder level, then horizontally adduct to scapular plane (scaption), approximately midway between abduction and flexion. Lightly adhere tape from C7-T1 vertebral spines to medial border of scapula at level of scapular spine.



Patient's thumb reaches toward opposite hip, then adhere tape firmly to skin.

TRICEPS BRACHII



ORIGIN

LONG HEAD:

Infraglenoid tubercle of scapula.

LATERAL HEAD:

Posterior surface of humerus, inferior to greater tubercle;

MEDIAL HEAD:

Posterior surface of humerus, inferior to radial groove.

INSERTION

Olecranon process of ulna.

NERVE C6 - C8

Radial nerve.

FUNCTION

As the name suggests, the triceps brachii has three heads and acts to extend the arm (long head) and forearm (long, lateral and medial heads). The long head also acts to steady the abducted humeral head.

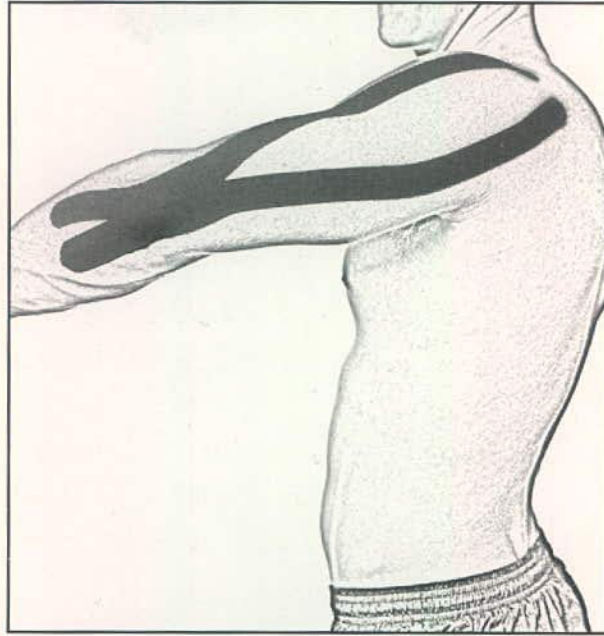
TAPE SPECIFICATIONS

WIDTH 2 in.
LENGTH 10-12 in.
X-SHAPED TAPE

CLINICAL APPLICATION

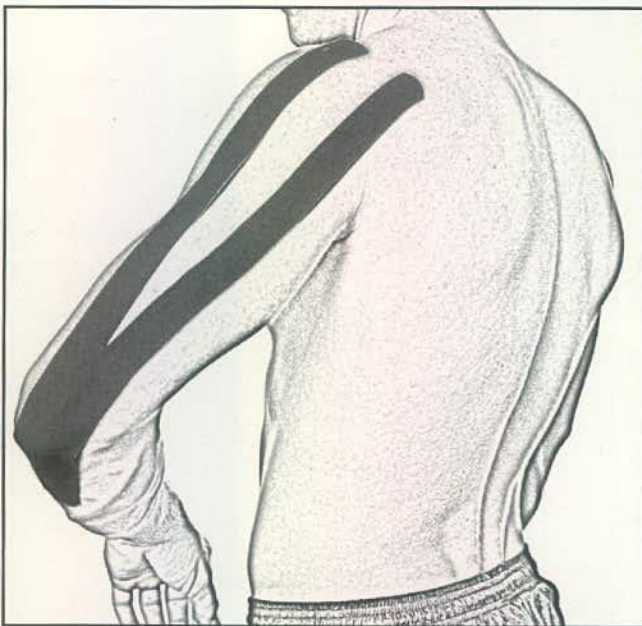
- Deformity of elbow joint.
- Tennis elbow pain on elbow flexion.

COMPLETED TAPING

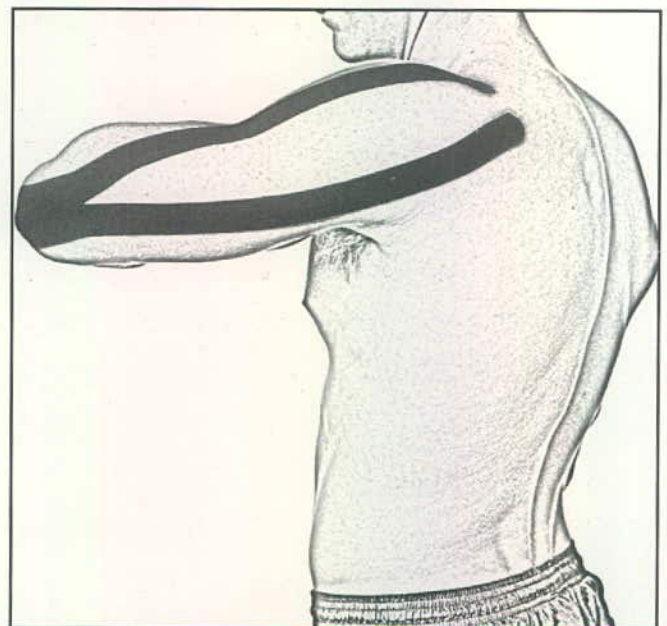


Triceps brachii tape when elbow joint is in maximum extension.

HOW TO ADHERE

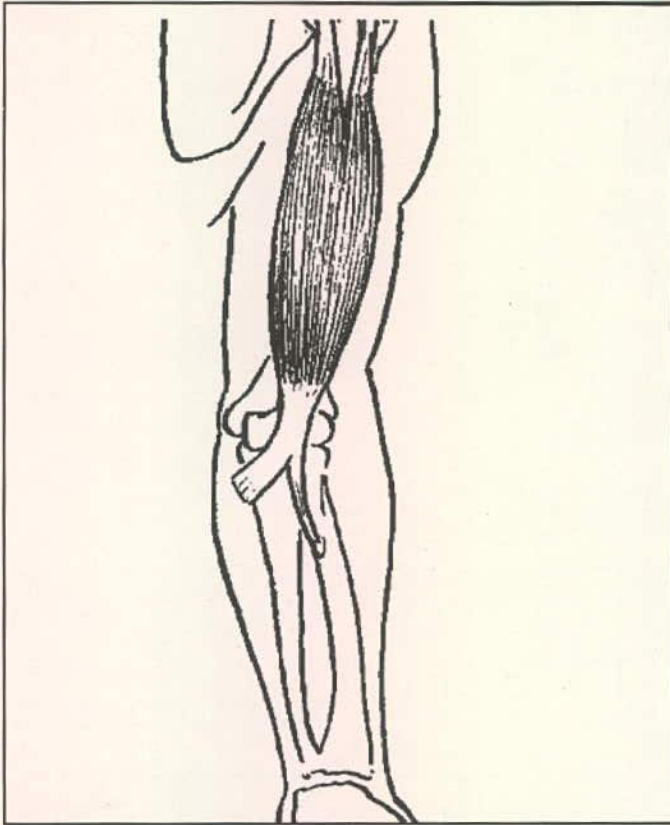


Arm flexed to 45° elbow extended. Point of upper tail attachment to tape base placed over tip of olecranon process. As elbow is gradually flexed to 90°, tape base applied over elbow joint and lower tape tails adhered to forearm.



With arm and elbow moderately flexed, ends of tape tails adhered to acromion, then tape tails applied as arm and forearm are fully flexed.

BICEPS BRACHII



ORIGIN

SHORT HEAD:

Coracoid process.

LONG HEAD:

Supraglenoid tuberosity of scapula.

INSERTION

Bicipital tuberosity of radius (radial tuberosity); fascia of forearm via bicipital aponeurosis.

NERVE C5 - C6

FUNCTION

Supinates forearm, and when it supinates it acts to flex forearm on the humerus. The biceps brachii also acts to flex the arm, and assists in stabilizing the anterior aspect of the humeral head within the glenoid cavity.

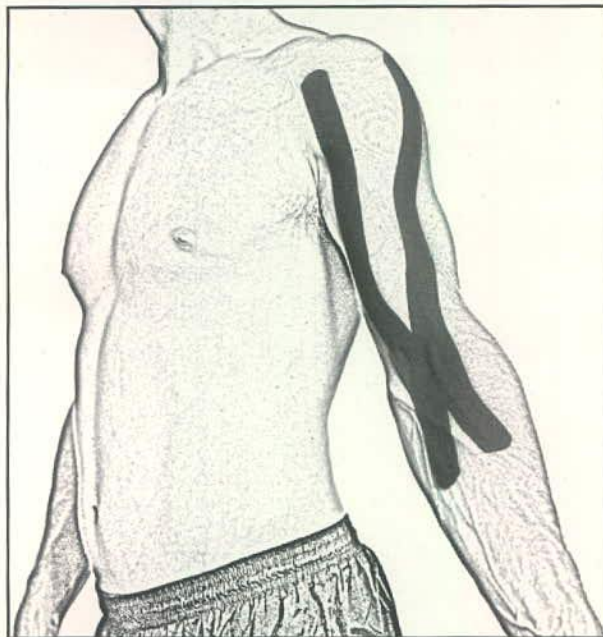
TAPE SPECIFICATIONS

WIDTH 2 in.
LENGTH 10 in.
X-SHAPED TAPE

CLINICAL APPLICATION

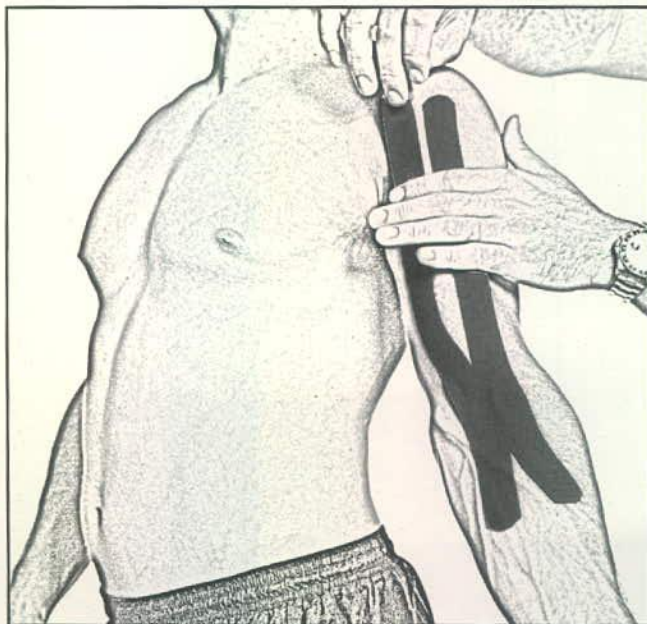
- Tennis elbow and other conditions where pain is elicited on elbow extension. Biceps tendonitis is usually caused by repetitive microtrauma to the tendon of the long head of the biceps brachii. Rupture of the long head tendon may result from chronic bicipital tendonitis, and may be seen in baseball pitchers and persons who perform heavy labor.

COMPLETED TAPING

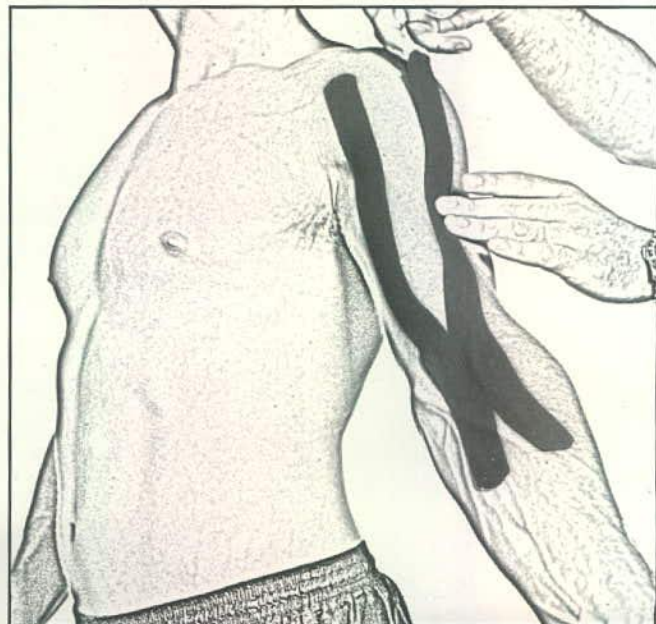


Biceps Brachii Taping in relaxed position

HOW TO ADHERE

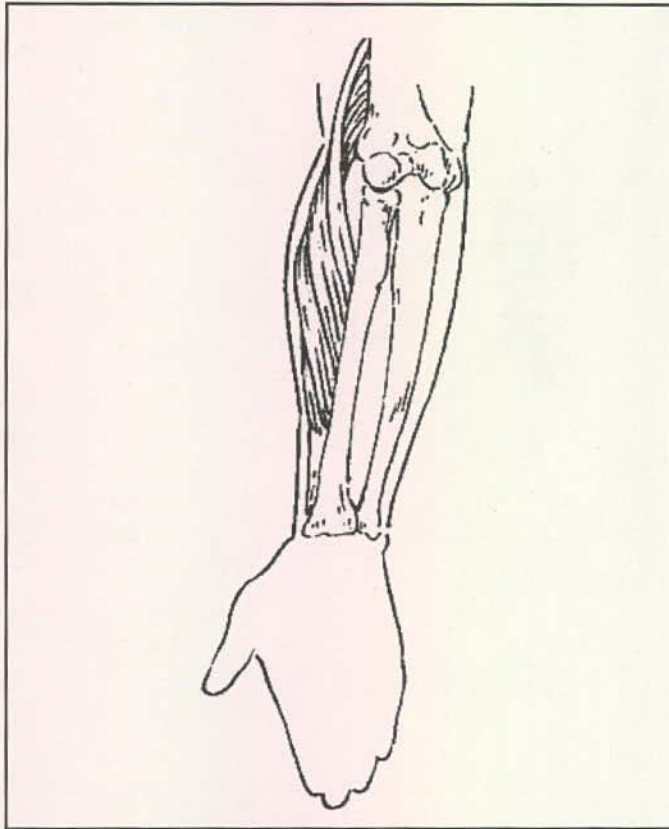


With elbow in slight flexion, adhere base of tape across cubital fossa. Apply lower tape tails to forearm.



With arm in external rotation and extension, apply medial upper tape tail being careful to not place tape within the axilla, and lateral upper tape tail is adhered along lateral border of biceps brachii muscle.

BRACHIORADIALIS



ORIGIN

Lateral supracondylar ridge of humerus.
Lateral intermuscular septum.

INSERTION

Front base of styloid process of radius.

NERVE C5 - C7

Radial nerve.

FUNCTION

The brachioradialis muscle is a strong flexor of the forearm. It can act either as a supinator or pronator of the forearm, but most commonly is a supinator of the forearm. The connection between the three flexors of the forearm is: the biceps brachii is primarily a supinator, the brachialis is the main flexor of the forearm in all positions, and the brachioradialis flexes the forearm as well as to bring the forearm into neutral (midway between pronation and supination).

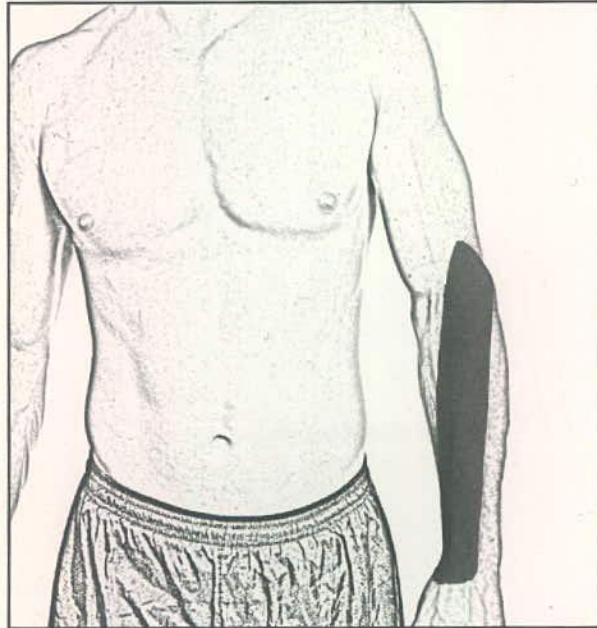
TAPE SPECIFICATIONS

WIDTH 2 in.
LENGTH 6-7 in.
I or Y-SHAPED TAPE

CLINICAL APPLICATION

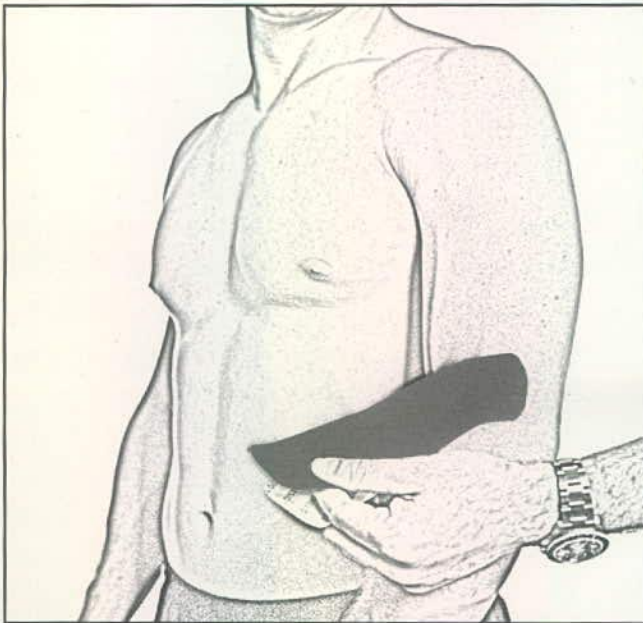
- Writer's cramp and pain along the brachioradialis.

COMPLETED TAPING

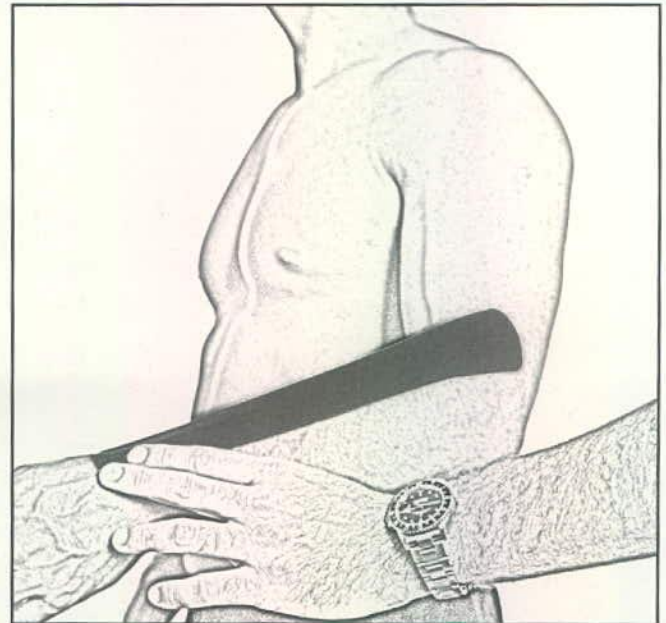


The completed Brachioradialis taping in relaxed position.

HOW TO ADHERE



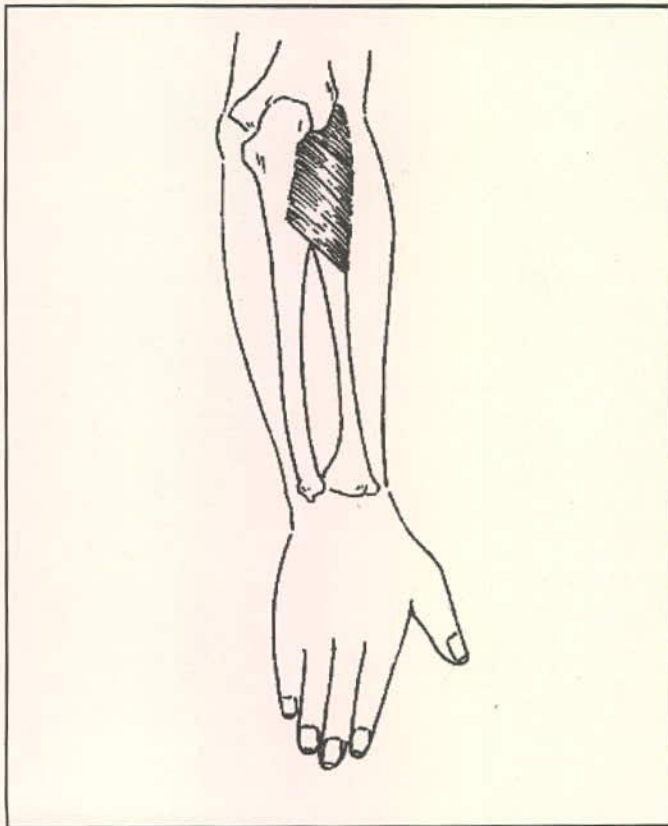
Supinate the forearm and flex elbow to about 45°. Adhere tape base to origin of brachioradialis muscle.



As the elbow gradually straightens the tape is placed toward the muscle insertion.

At almost maximum extension the tape is adhered.

SUPINATOR



ORIGIN

Lateral humeral epicondyle
Radial collateral and annular ligaments
Crest of ulna.

INSERTION

Lateral, anterior and posterior surfaces
of upper 1/3 of radius.

NERVE C6

FUNCTION

Divided into superficial and deep layers, the supinator muscle, together with biceps brachii, supinates the forearm. When the supinator becomes weak, the biceps brachii alone cannot completely supinate the forearm. This suggests that the supinator muscle is the primary forearm supinator. Also, the deep branch of the radial nerve pierces the supinator and may become compressed.

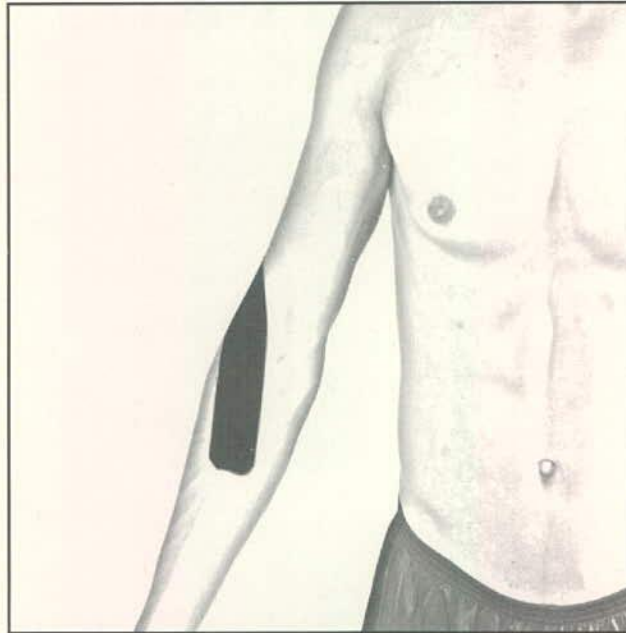
TAPE SPECIFICATIONS

WIDTH 2 in.
LENGTH 7-8 in.
I-SHAPED TAPE

CLINICAL APPLICATION

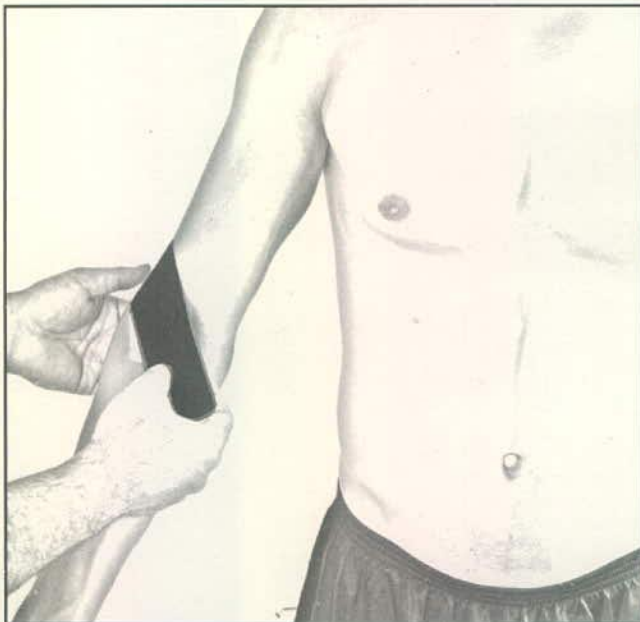
- Extreme pain on resisted supination and full extension of the forearm and in conditions such as tennis elbow.

COMPLETED TAPING

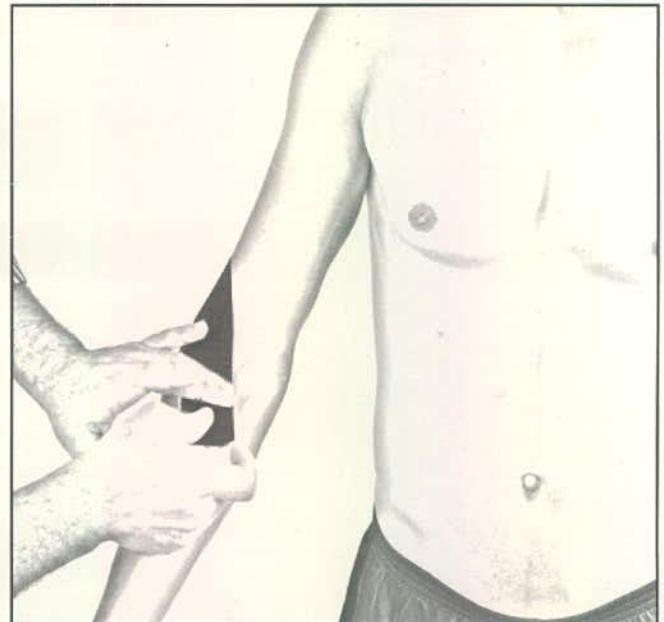


Supinator tape with arm in relaxed position.

HOW TO ADHERE

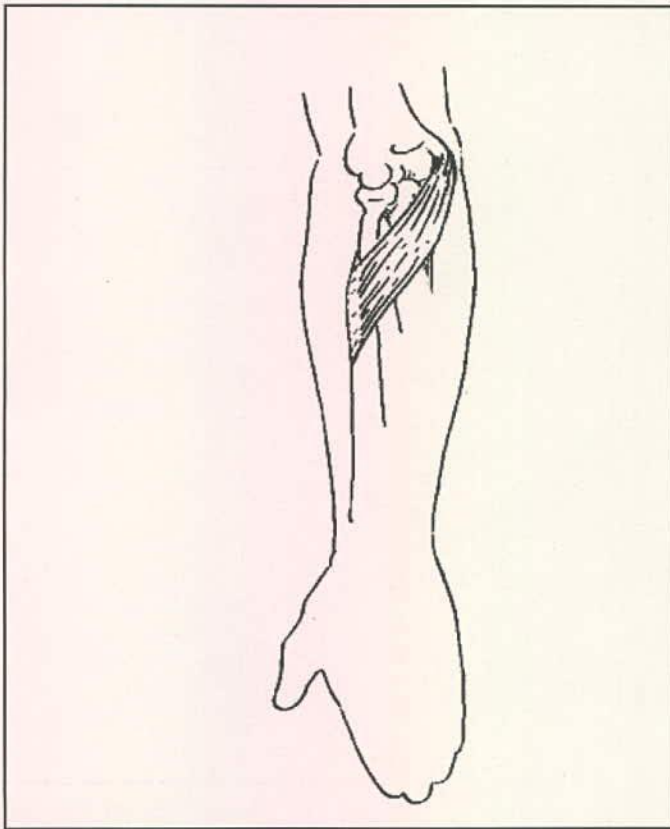


Apply tape base to posterior aspect of arm over olecranon process with tape oriented toward lateral aspect of forearm. Hyperpronate the forearm and allow slight elbow flexion.



Apply tape along course of supinator muscle as the forearm is brought into full supination and extension. Tape should end on the middle of the ulna.

PRONATOR TERES



ORIGIN

Medial humeral epicondyle and coronoid process of ulna.

INSERTION

Middle of outer surface of the radius.

NERVE C6 - C7

FUNCTION

Pronates forearm and flexes elbow joint. The pronator quadratus, located in the distal forearm, assists pronator teres in pronation of the forearm.

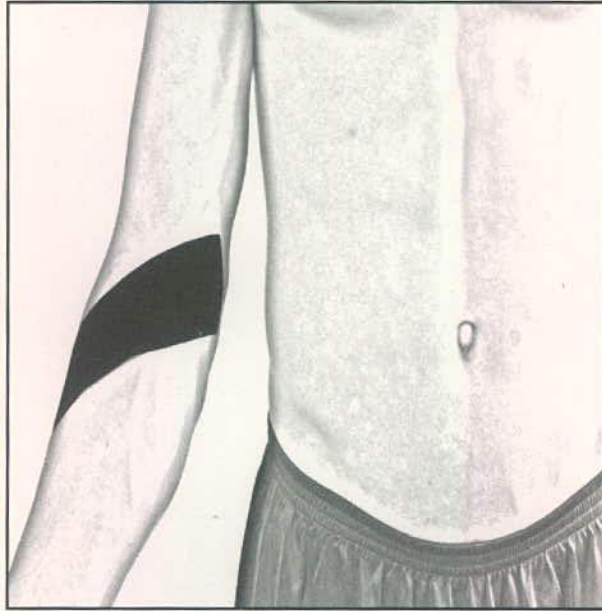
TAPE SPECIFICATIONS

WIDTH 2 in.
LENGTH 8-10 in.
I-SHAPED TAPE

CLINICAL APPLICATION

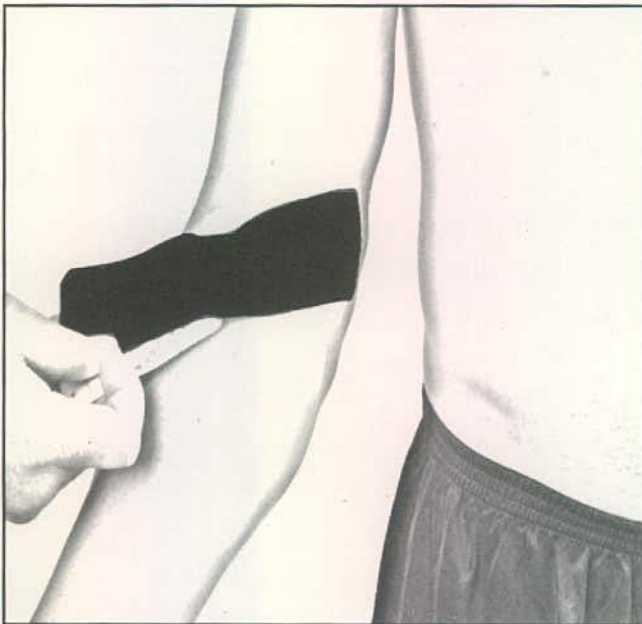
- Extreme pain on pronation of the forearm and in conditions such as golfer's elbow.

COMPLETED TAPING

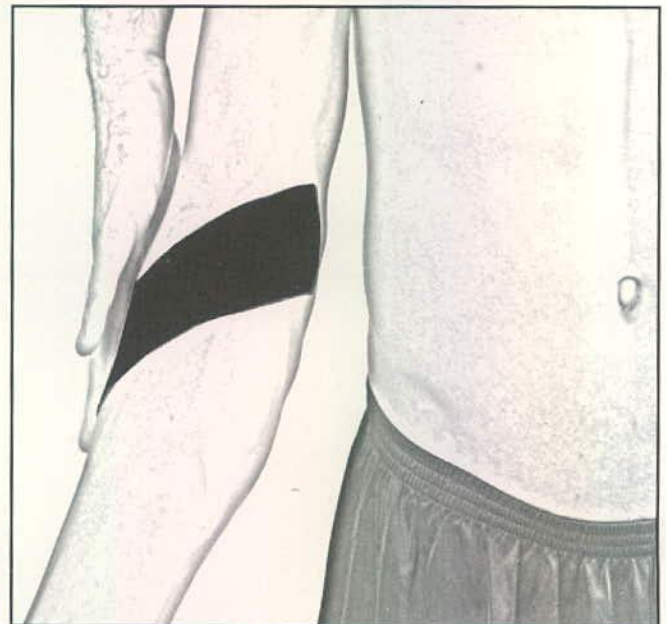


Pronator Teres Taping in relaxed position

HOW TO ADHERE

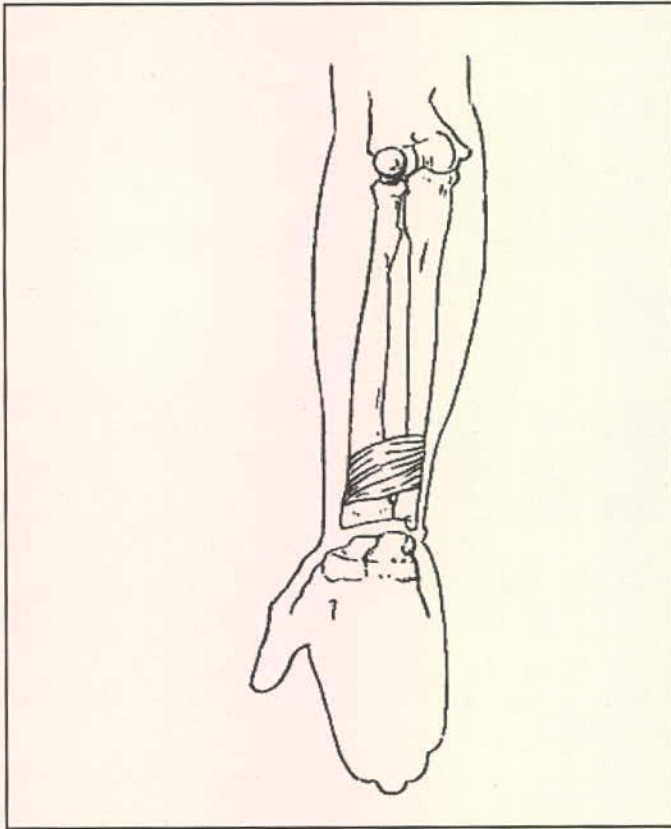


Adhere tape base to the posterior aspect of arm over olecranon process with tape oriented toward medial aspect of forearm. Hypersupinate the forearm and allow slight elbow flexion.



Apply tape along course of pronator teres muscle as the forearm is brought into full pronation and extension. Tape should end on the middle of the radius.

PRONATOR QUADRATUS



ORIGIN

Lower fourth of the anterior surface of ulna.

INSERTION

Lower fourth of the anterior surface of radius.

NERVE C8, Th1

FUNCTION

The pronator quadratus, together with the pronator teres, pronates the forearm. The pronator quadratus has a large effect on forearm pronation compared to that of pronator teres. The deep fibers of pronator quadratus muscle bind the ulna and radius together.

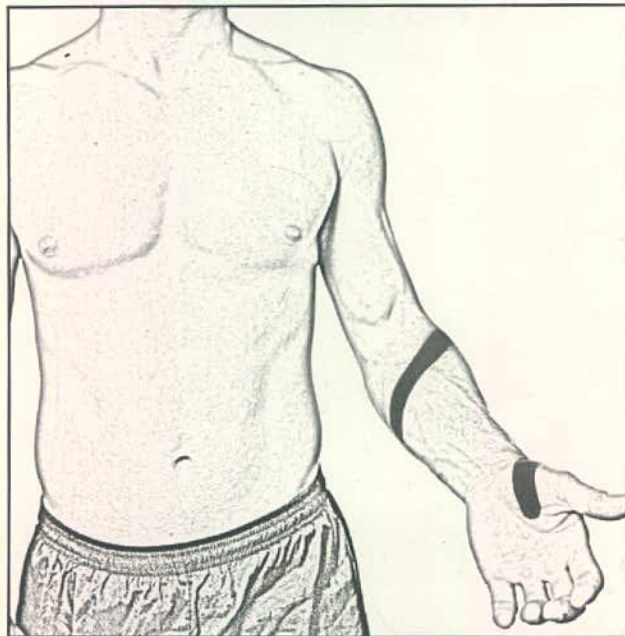
TAPE SPECIFICATIONS

WIDTH 1 in.
LENGTH 8-10 in.
I-SHAPED TAPE

CLINICAL APPLICATION

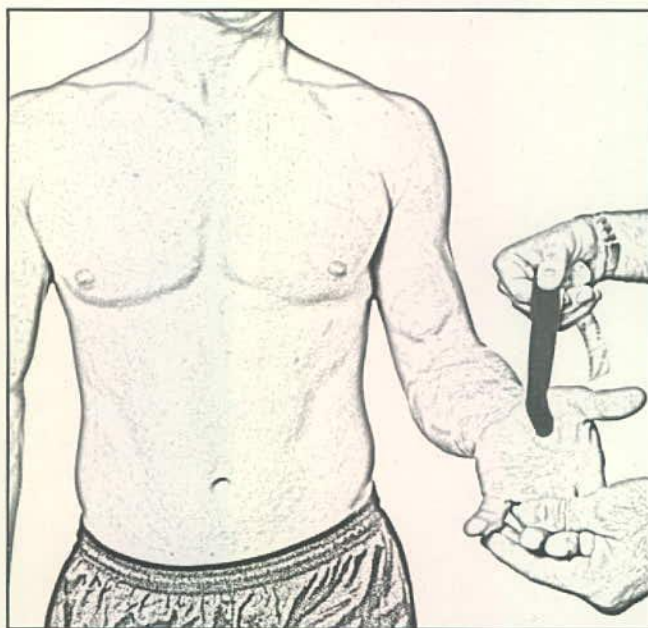
- Pain on internal rotation of forearm and/or wrist, de Quervain syndrome, carpal tunnel syndrome.

COMPLETED TAPING

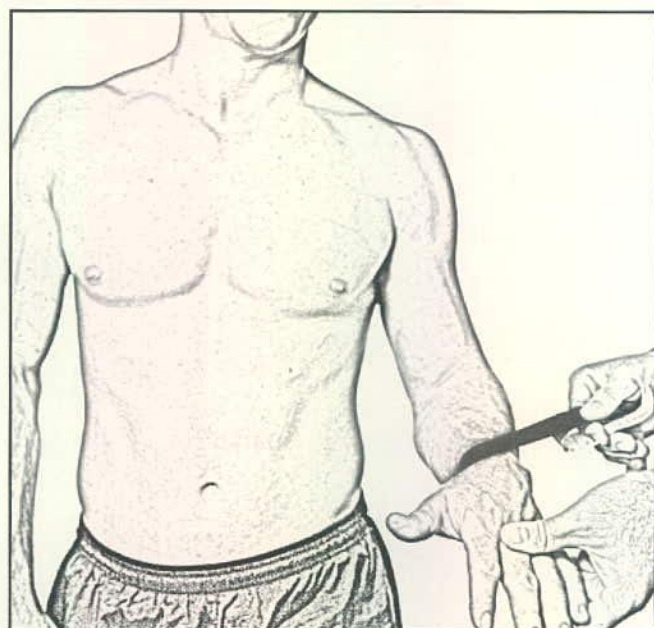


Pronator Quadratus Taping

HOW TO ADHERE

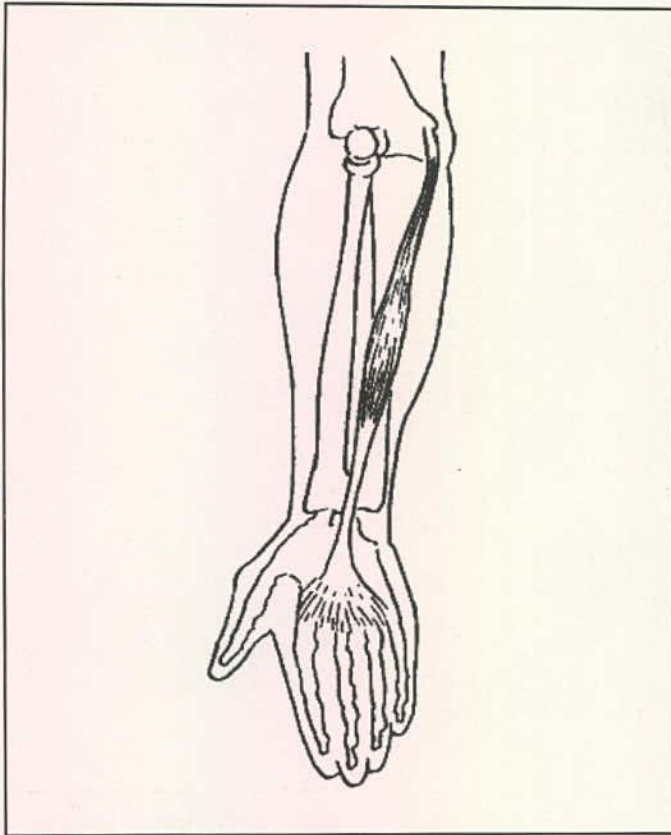


Fully supinate forearm. Adhere the tape to the base of the thumb.



As the forearm is gradually brought into pronation, apply tape over the dorsum of the wrist and spiral towards the volar (anterior) forearm. Adhere the tape towards the lateral humeral epicondyle to finish.

PALMARIS LONGUS



ORIGIN

Medial condyle of humerus.

INSERTION

Flexor retinaculum of wrist and palmar fascia.

NERVE C7 - C8

Median nerve.

FUNCTION

The palmaris longus acts to flex the hand at the wrist, and to tighten palmar aponeurosis. Recently tennis players and golfers seem to be suffering from wrist problems labeled as "elbow syndromes."

It cannot be said that this is due only to abnormal function. However, if insufficient practice or spinal abnormalities are the cause, then muscle imbalance will be found. These imbalances, whether in primary or secondary movers or stabilizers, will elicit symptoms related to the forearm movement.

TAPE SPECIFICATIONS

WIDTH 1 in.

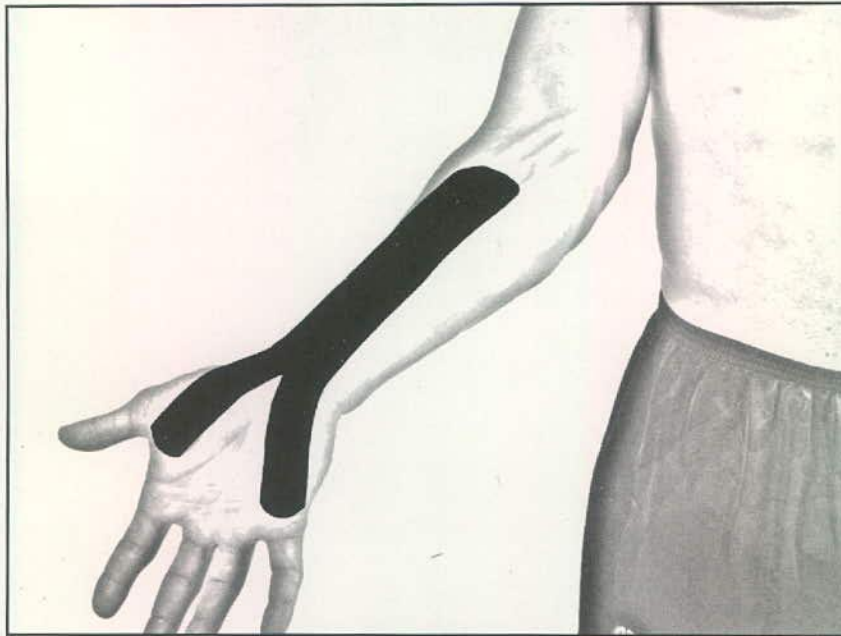
LENGTH 8 in.

Y-SHAPED TAPE

CLINICAL APPLICATION

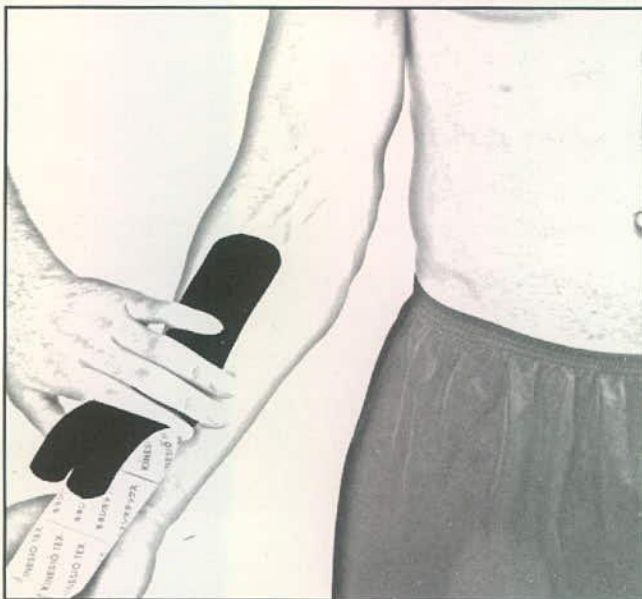
- Dupuytren's contracture, carpal tunnel syndrome.

COMPLETED TAPING

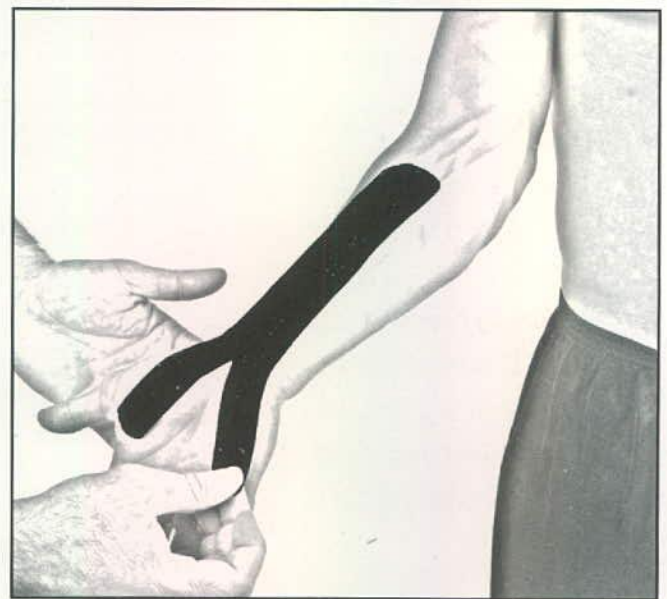


Palmaris Longus Taping in relaxed position.

HOW TO ADHERE

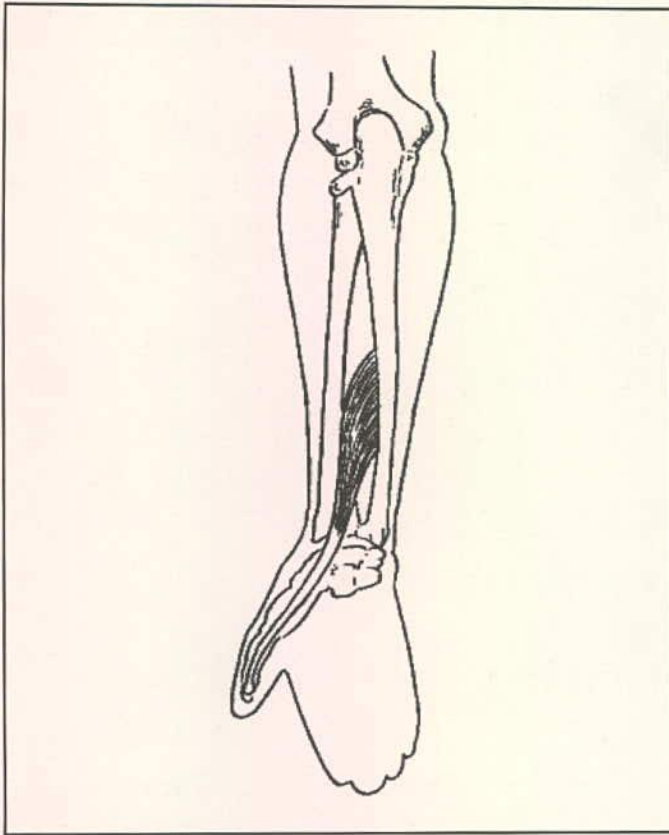


Slightly flex the elbow and wrist. Adhere tape over palmaris longus from elbow to wrist (proximal to distal).



Fully extend elbow and wrist, adhere tape to the palm to finish.

EXTENSOR POLLICIS LONGUS



ORIGIN

Central 1/3 of posterior surface of ulna.
Interosseus membrane.

INSERTION

Dorsal surface of base of distal phalanx
of thumb.

NERVE C7 - C8

Radial nerve.

FUNCTION

Wrist extension and hyper extension are controlled by the extensor carpi radialis longus and brevis and the extensor carpi ulnaris muscles, while the extensor pollicis longus and brevis, extensor indices (2 fingers) and extensor digiti minimi muscles act as helpers.

Extension of the fingers depends on the extensor digitorum, extensor indicis and extensor digiti minimi muscles. The phalangeal joints are comprised of the metacarpophalangeal (MCP), proximal interphalangeal (PIP), and distal interphalangeal (DIP) joints. Recently, this extensor group has come under imbalance due to today's life style and working conditions.

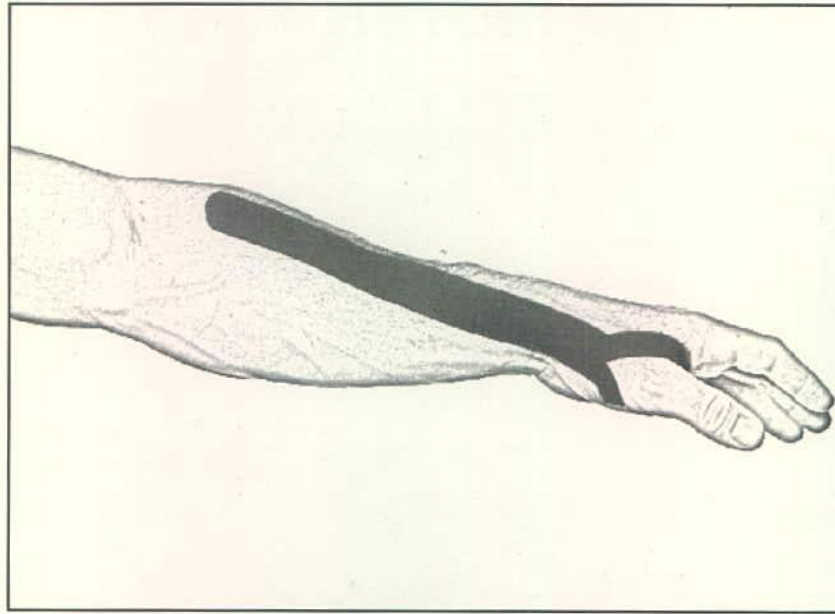
TAPE SPECIFICATIONS

WIDTH 1 in.
LENGTH 8 in.
Y-SHAPED TAPE

CLINICAL APPLICATION

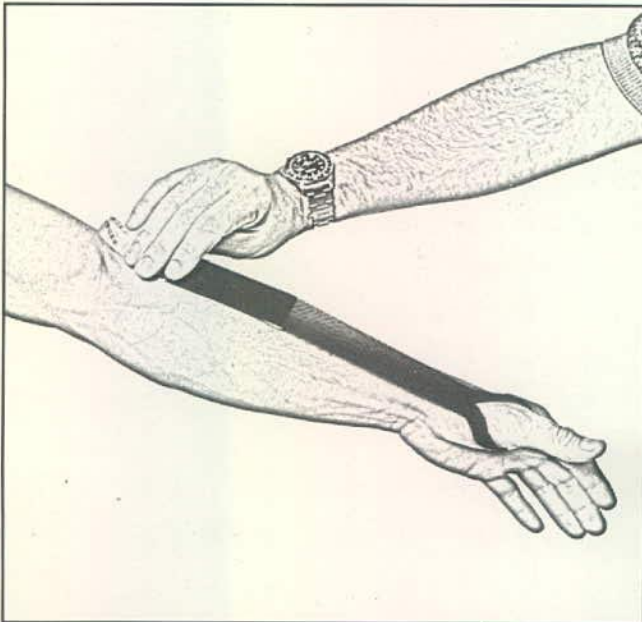
- Ganglion, extensor tendonitis.

COMPLETED TAPING

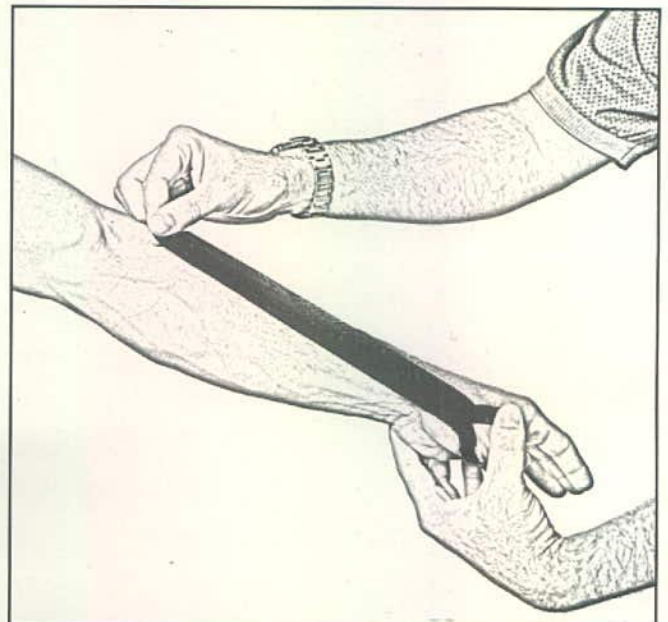


Extensor Pollicis Longus Taping in arm streched.

HOW TO ADHERE

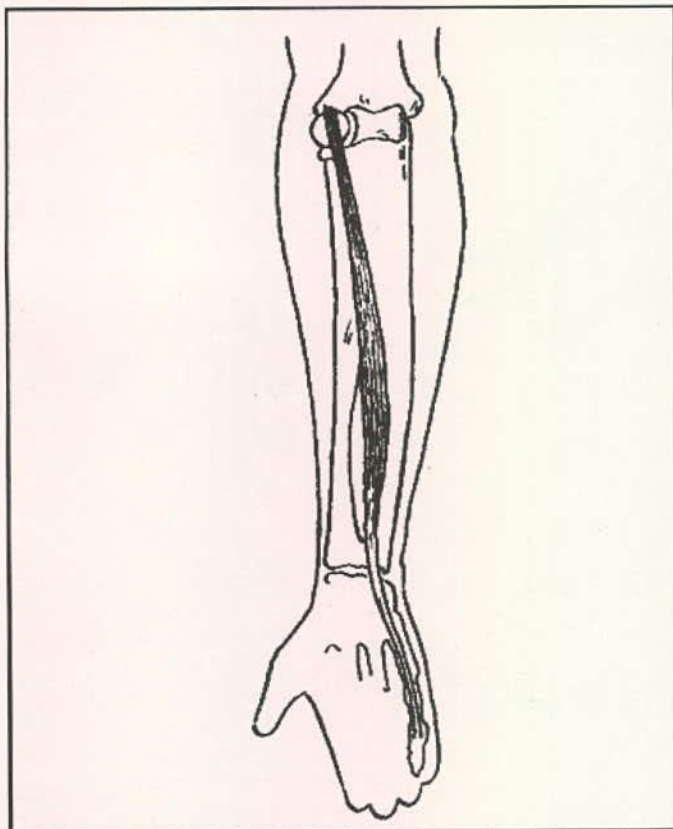


Place the point of the "Y" over the base of the thumb on the dorsal surface. Adhere the tape tails around the thumb.



Flex thumb joints fully. Apply tape to base of thumb then along the course of the muscle.

EXTENSOR DIGITI BREVIS



ORIGIN

Lateral epicondyle of humerus.

INSERTION

Dorsum of first phalanx of little finger.

NERVE C7 - C8

Radial nerve.

FUNCTION

Wrist extension and hyper-extension are controlled by the extensor carpi radialis longus and brevis and the extensor carpi ulnaris muscles, while the extensor pollicis longus and brevis, extensor indices (2 fingers) and extensor digiti minimi muscles act as helpers. Extensor pollicis longus, because it crosses 2 joints in the thumb, assists extensor pollicis brevis in extension of the proximal phalanx.

Extension of the fingers depends on the extensor digitorum, extensor indicis and extensor digiti minimi muscles. The phalangeal joints are comprised of the metacarpophalangeal (MCP), proximal interphalangeal (PIP), and distal interphalangeal (DIP) joints. Recently, this extensor group has come under imbalance due to today's life style and working conditions.

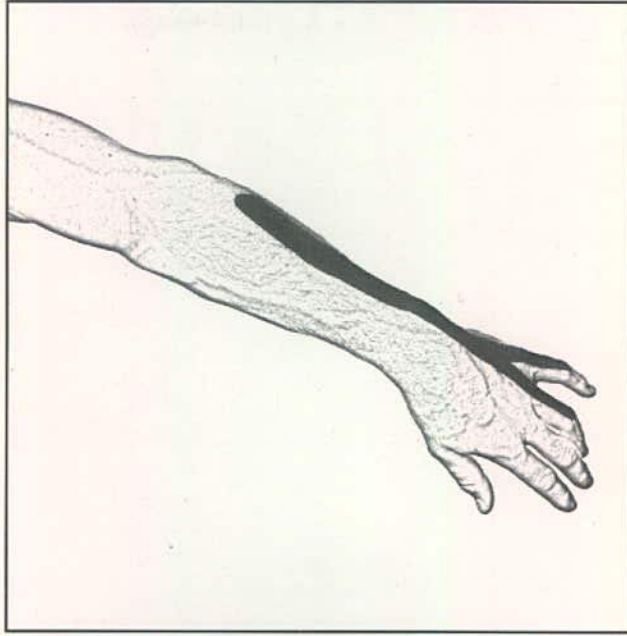TAPE SPECIFICATIONS

WIDTH 1 in.
LENGTH 10-12 in.
Y-SHAPED TAPE

CLINICAL APPLICATION

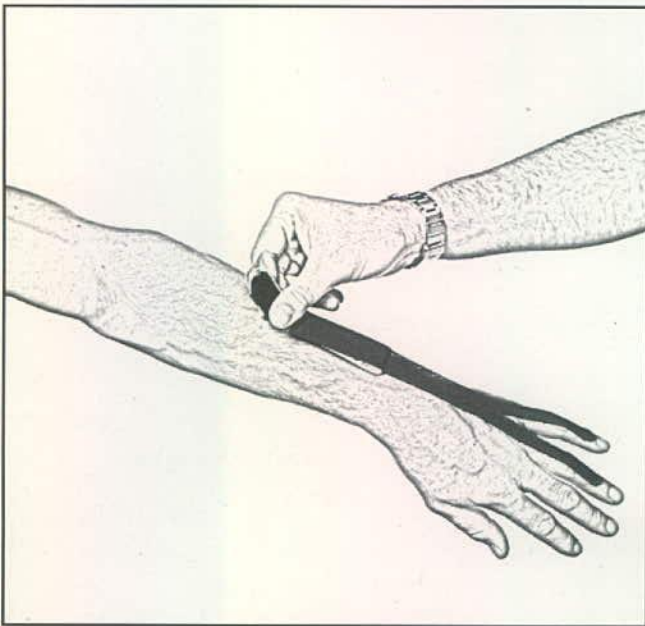
- Ulna pain, inflammation of tendon sheath of little finger.

COMPLETED TAPING

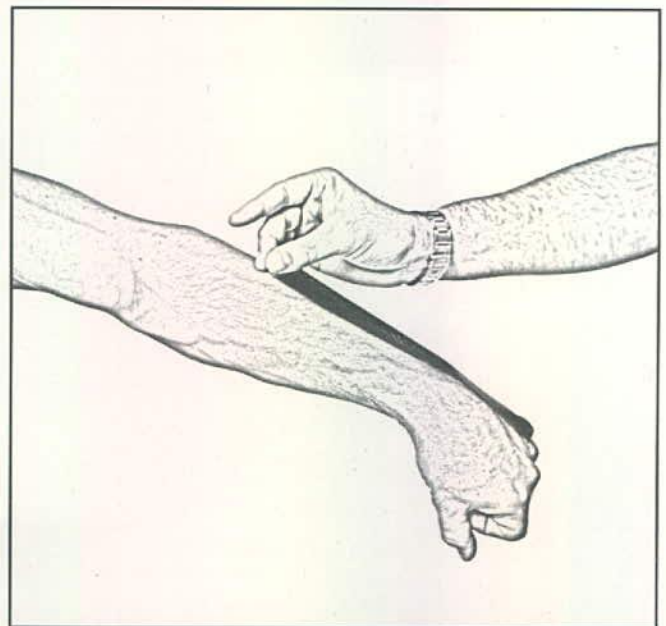


Since this taping easily comes off, separate tapes may be wrapped around each fingers.

HOW TO ADHERE

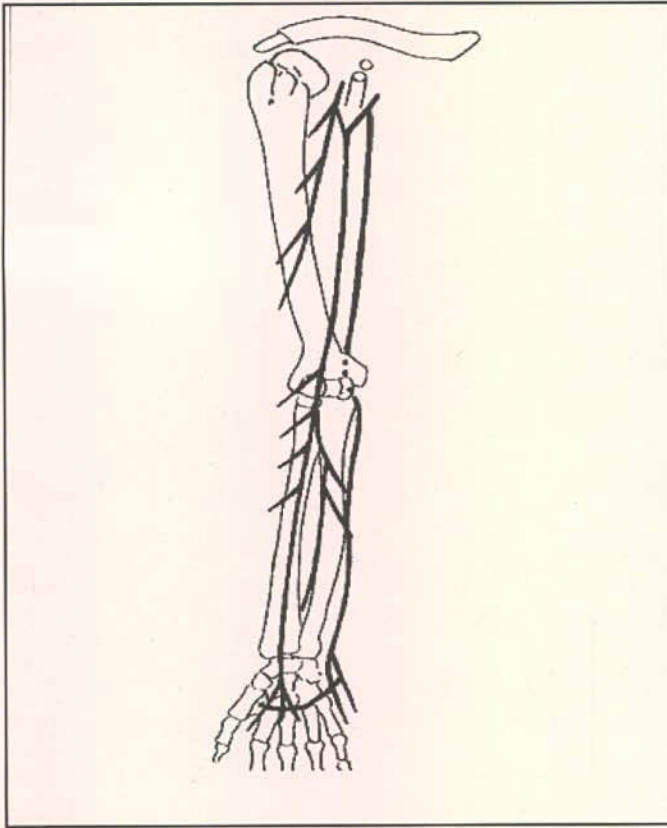


Adhere the point of the "Y" to the dorsum of the hand. Adhere tape half way along the extensor digiti tendon.



Patient clenches their fist with wrist in extension, then tape tails are adhered to little and ring fingers. Maintain clenched fist and flex wrist; adhere tape along the course of the muscle.

BRACHIAL PLEXUS TAPE



ARM AND FOREARM

The region from the axilla to the elbow is known as the arm (upper arm), and from the elbow to the wrist is the forearm. The front of anterior surface of the arm and forearm is separated from the back or posterior surface. The anterior (palmar or volar) muscles act in flexion while the posterior (dorsal) muscles work in extension.

In the upper extremity the arm is connected to the forearm by the elbow joint, and the hand is connected to the forearm by the wrist.

NERVE BRANCHES OF THE UPPER EXTREMITY

The nerves of the upper extremity consist of the brachial plexus and its branches. The spinal nerve roots of this plexus originate from C5, C6, C7, C8 and T1. There is also some contribution from C4.

As the nerve roots pass between the anterior and middle scalene muscles in the neck, they group together to form the upper (C5, C6), middle (C7) and lower (C8, T1) trunks of the plexus. Deep to the middle of the clavicle, the trunks split into anterior and posterior divisions. The anterior divisions then separate into medial and lateral cords while the posterior division changes its name to posterior cord. The final branches from the cords are named as peripheral nerves which innervate the upper extremity structures.

The peripheral nerve branches and the muscles they innervate are as follows. The dorsal scapular nerve to the rhomboids, the suprascapular nerve to supraspinatus and infraspinatus, the nerve to subclavius muscle, and the long thoracic nerve to the serratus anterior muscle all come from the nerve roots and trunks of the plexus. No nerves come from the level of the divisions.

The medial cord gives rise to the medial pectoral nerve to the pectoralis minor and major muscles, a branch that will aid in forming the median nerve and the ulnar nerve. The lateral cord of the plexus gives rise to the lateral pectoral nerve which innervates pectoralis major but

not minor, a branch that aids in forming the median nerve, and the musculocutaneous nerve that innervates coracobrachialis, biceps brachii and brachialis muscles. The posterior cord gives off the axillary nerve to the deltoid and teres minor muscles, the upper and lower subscapular nerves that innervate the subscapularis muscle, the middle subscapular (also called the thoracodorsal) nerve goes to the latissimus dorsi muscle, and the radial nerve.

The ulnar nerve innervates the flexor carpi ulnaris and part of the flexor digitorum profundus, then travels to the hand where it is motor to the muscles associated with the little finger and the deep intrinsic hand muscles (dorsal and volar interossei, and adductor pollicis). It is also sensory to the volar and dorsal surfaces of the little finger and half of the ring finger.

The radial nerve innervates all of the extensor muscles of the arm (triceps brachii, anconeus, supinator, brachioradialis), then divides into a deep branch which innervates all of the extensor muscles of the forearm (extensor carpi radialis longus and brevis, extensor digitorum, extensor pollicis longus and brevis, extensor indicis, extensor ulnaris, abductor pollicis longus). The superficial branch of the radial nerve travels to the dorsum of the hand where it is a sensory nerve.

The median nerve innervates the flexor muscles of the forearm including the palmaris longus, flexor carpi radialis, flexor carpi ulnaris, pronator teres, flexor digitorum superficialis, part of the flexor digitorum profundus, flexor pollicis longus and pronator quadratus. The nerve then travels into the hand where it gives off a motor nerve to the short muscles of the thumb (flexor pollicis brevis, abductor pollicis brevis and opponens pollicis) and a sensory nerve that supplies the volar surface of the thumb, index and long fingers, and half of the ring finger.

CERVICAL SYNDROME (Shoulder-arm-neck syndrome)

The brachial plexus peripheral nerves may cause paresthesia (numbness, tingling sensations) or pain in the upper extremity. These symptoms and associated signs may be described as cervical disc or cervical vertebral syndrome.

It is not uncommon that inflammation of peripheral nerves, without necessarily having a direct link to the cervical vertebrae, can cause stiff neck and shoulder pain. Certain occupational overuse conditions of the upper extremity may cause chronic inflammation of the brachial plexus components.

Generally, brachial plexus syndrome, cervical pain, shoulder pain, arm pain and paresthesias are grouped together as shoulder-arm-neck syndrome (cervical syndrome).

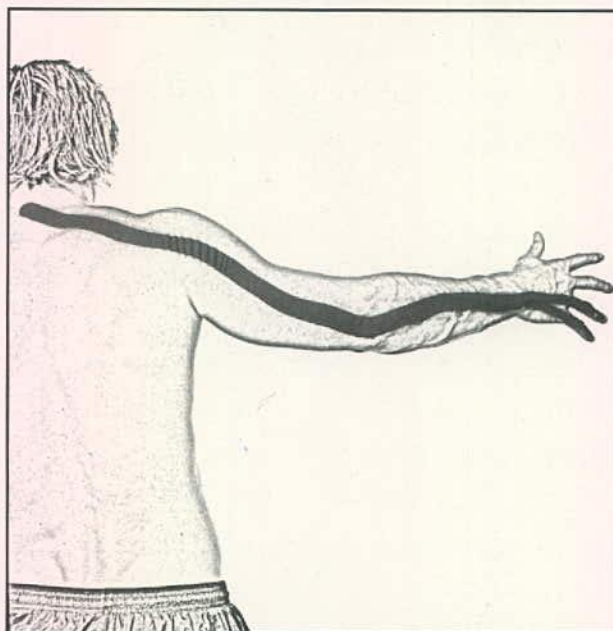
TAPE SPECIFICATIONS

WIDTH 1 in.

LENGTH 28 in.

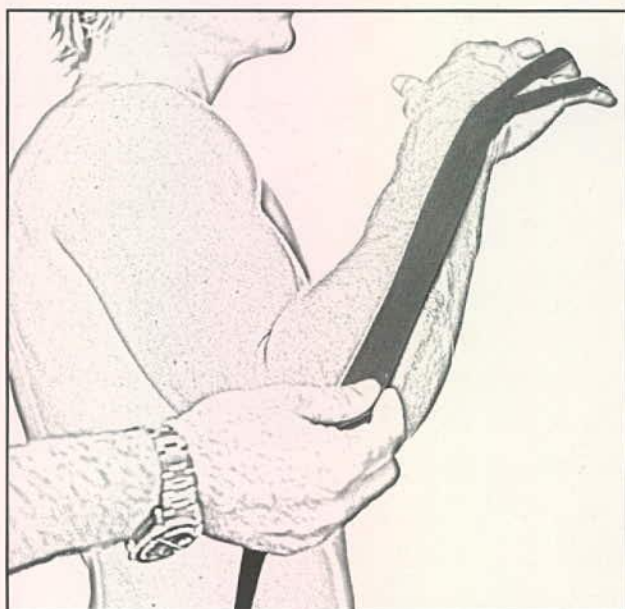Y-SHAPED TAPE

COMPLETED TAPING



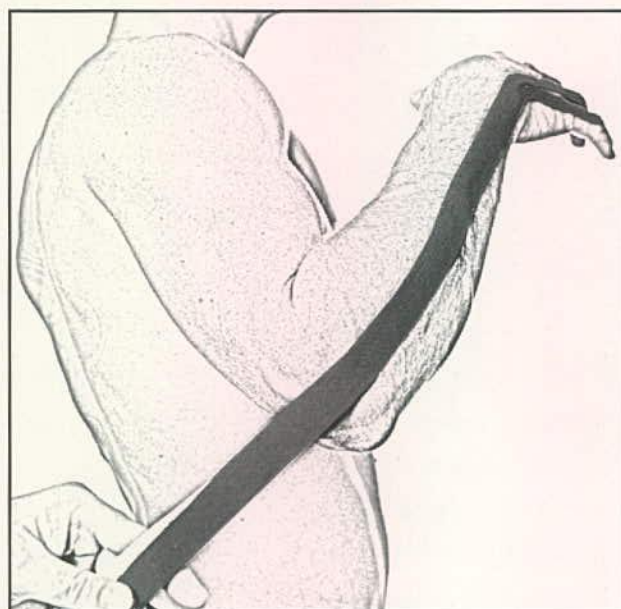
Brachial Plexus Taping from back.

HOW TO ADHERE



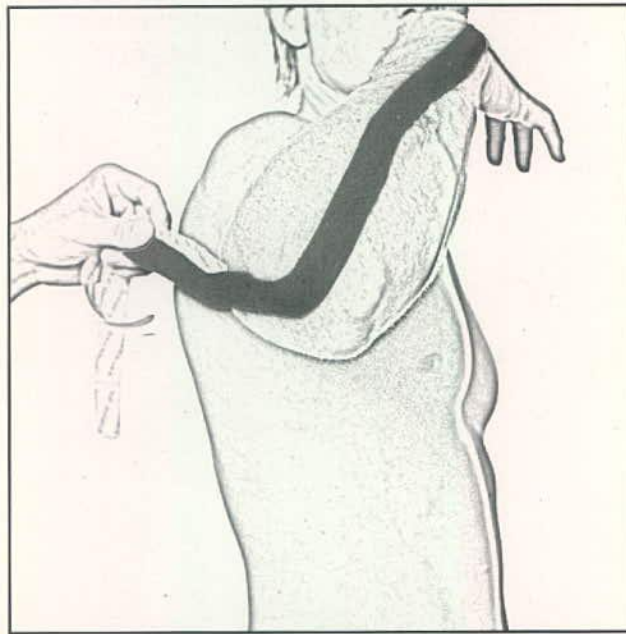
Seated and upper extremity extended forward and stabilized.

Adhere "V" section of tape to 4th and 5th carpo-metacarpo joints in extension.

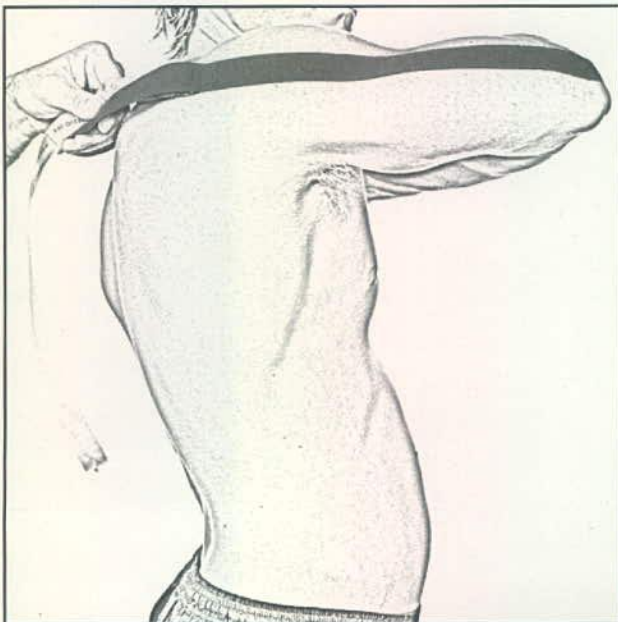


While flexing wrist, tape is adhered just above that area.

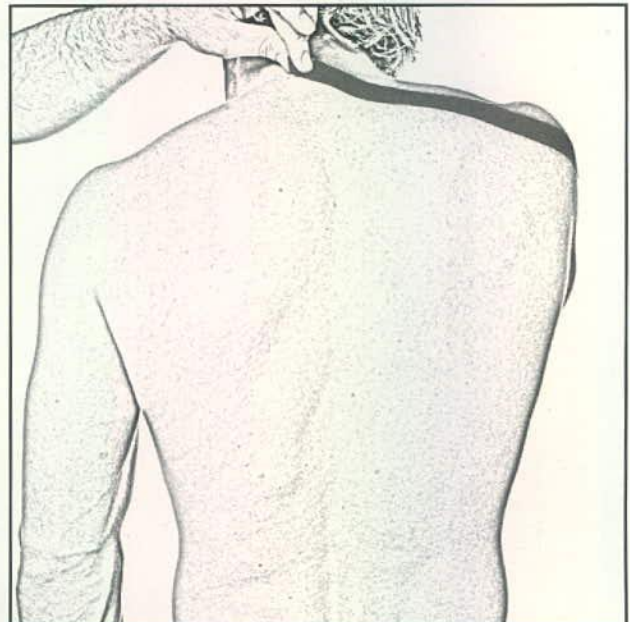
Extend wrist, straighten elbow, then affix tape to upper arm as wrist and elbow are flexed.



Next extend wrist and elbow to maximum and adhere tape (pass over lateral head of olecranon).



Gradually take arm across chest in a parallel line. Extend elbow, and pull tape to posterior section of shoulder



Flex elbow taking arm across chest in a parallel line. Affix tape over upper part of scapula as far as spinous process of first thoracic vertebrae.

TRUNK

Scalenus Anterior

Scalenus Posterior

Sternocleidomastoid

Latissimus Dorsi

Upper Trapezius

Middle Trapezius

Lower Trapezius

Rectus Abdominis

External Abdominis Oblique

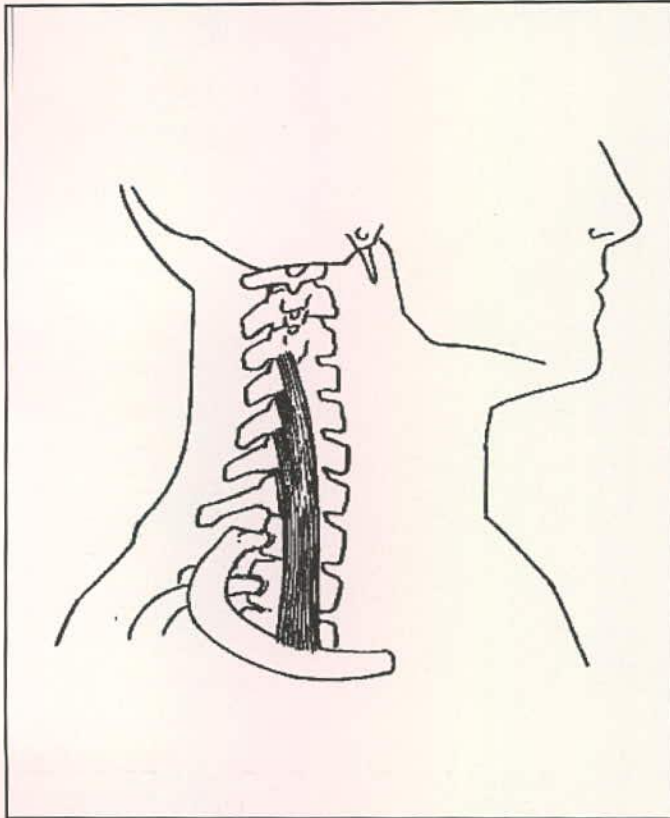
Internal Abdominis Oblique

Diaphragm Anterior

Diaphragm Posterior

Erector Spinae

SCALENUS ANTERIOR



ORIGIN

Anterior tuberosities of transverse processes of 3rd to 6th cervical vertebrae.

INSERTION

Scalene tubercle of 1st rib (medial 2/3rds)

NERVE C5, C6

FUNCTION

The scalene muscles as a group act unilaterally as lateral flexors and bilaterally as anterior flexors of the cervical spine. They also rotate the neck to the opposite side when used unilaterally. The scalene muscles elevate the 1st and 2nd ribs during inspiration, so they have a large influence on respiration.

The involvement of the anterior scalene can be detected when the neck is flexed to the painful side where the referred pain extends from the 3rd to 4th cervical vertebrae to the upper border of the clavicle. The referral pattern from posterior scalene is from mid-cervical levels to the upper shoulder region as well as the medial border of the scapula.

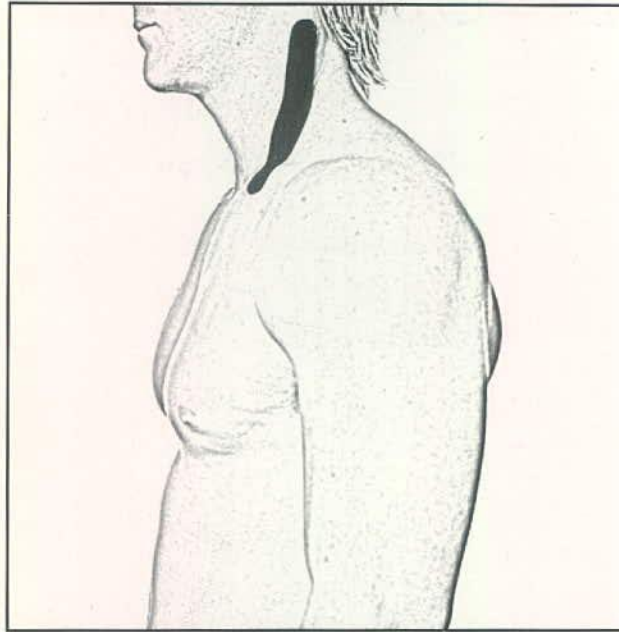
TAPE SPECIFICATIONS

WIDTH 1 in.
LENGTH 4 in.
I-SHAPED TAPE

CLINICAL APPLICATION

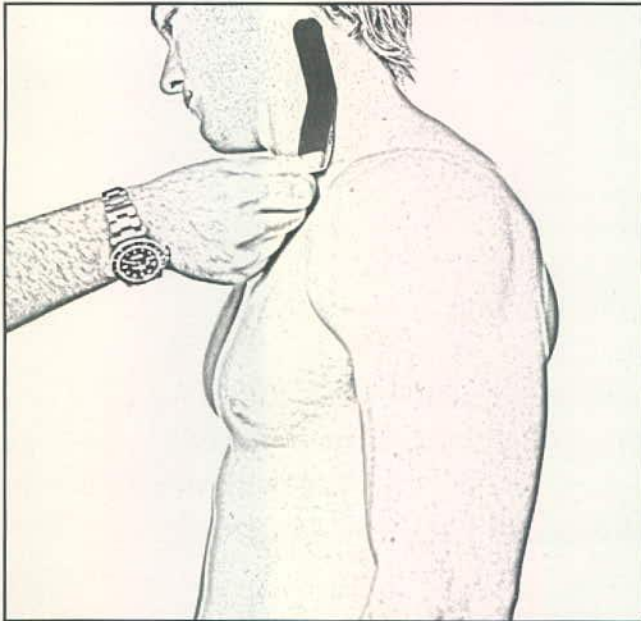
- Scalenus anterior symptoms, cervical spine syndrome, thoracic outlet syndrome, shoulder girdle symptoms.

COMPLETED TAPING

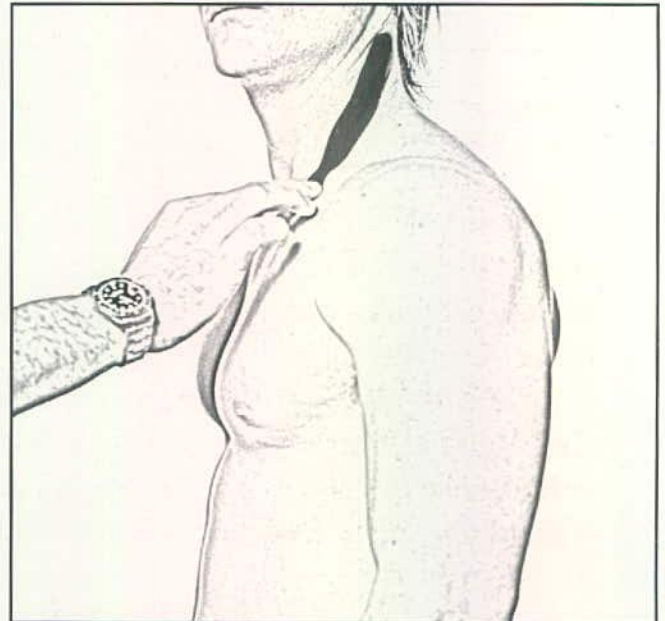


The completed Scalenus Anterior Taping in relaxed position.

HOW TO ADHERE

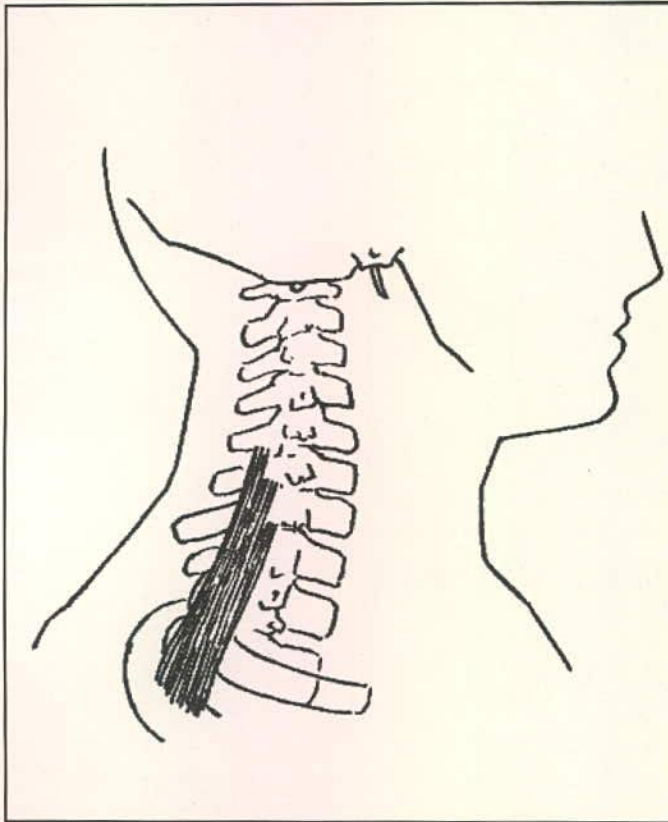


Apply tape to insertion about $\frac{1}{3}$ distance out along clavicle.



Gradually rotate neck towards the involved side and side bend away from the taped side. Adhere along side of neck to finish.

SCALENUS POSTERIOR



ORIGIN

Posterior tubercles of transverse processes of 4th to 6th cervical vertebrae.

INSERTION

Outer surface of upper border of 2nd rib.

NERVE C7, C8

FUNCTION

The scalene muscles as a group act unilaterally as lateral flexors and bilaterally as anterior flexors of the cervical spine. They also rotate the neck to the opposite side when used unilaterally. The scalene muscles elevate the 1st and 2nd ribs during forced inspiration, so they have a large influence on respiration.

The involvement of the anterior scalene can be detected when the neck is flexed to the painful side where the referred pain extends from the 3rd to 4th cervical vertebrae to the upper border of the clavicle. The referral pattern from posterior scalene is from mid-cervical levels to the upper shoulder region as well as the medial border of the scapula.

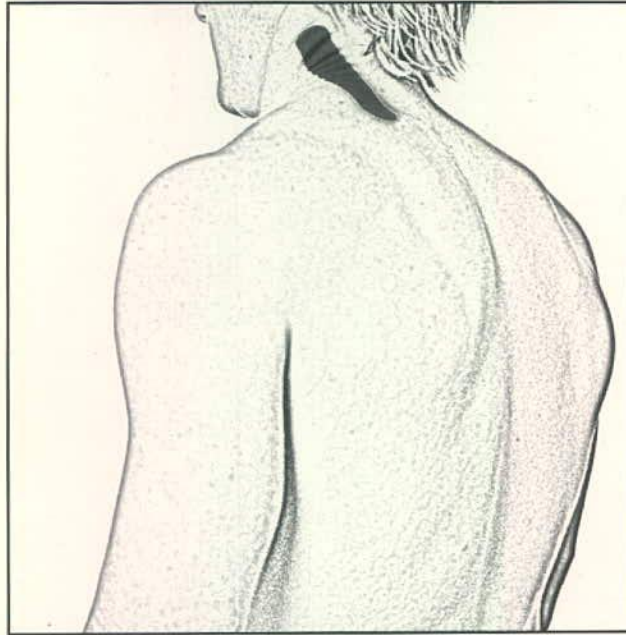
TAPE SPECIFICATIONS

WIDTH 1 in.
LENGTH 4 in.
I-SHAPED TAPE

CLINICAL APPLICATION

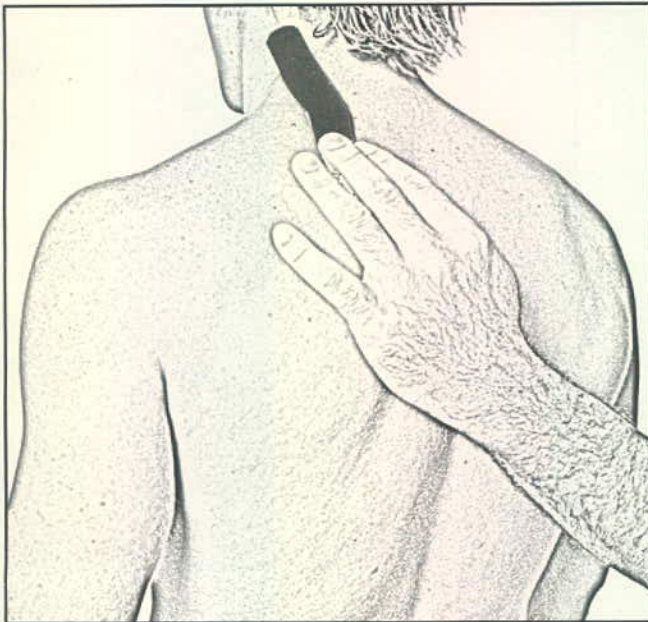
- Cervical sprain, cervical spine syndrome, shoulder girdle syndromes, cervical disc hernia.

COMPLETED TAPING

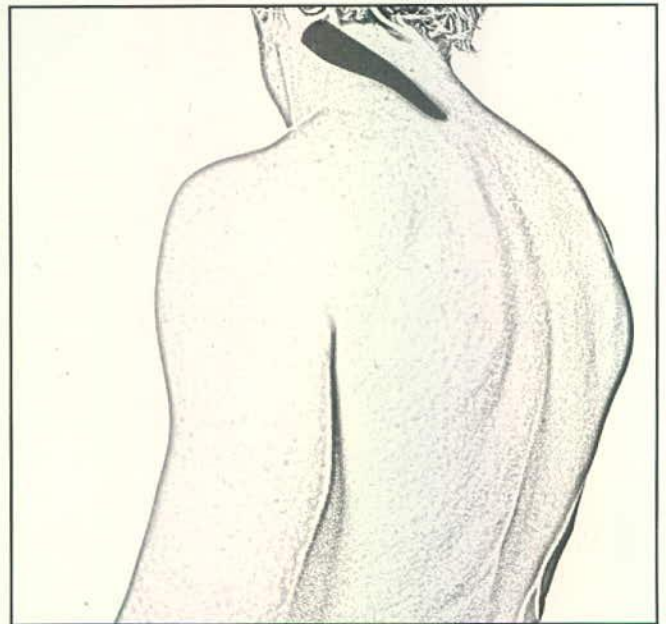


The completed Scaleneus Posterior Taping in relaxed position.

HOW TO ADHERE

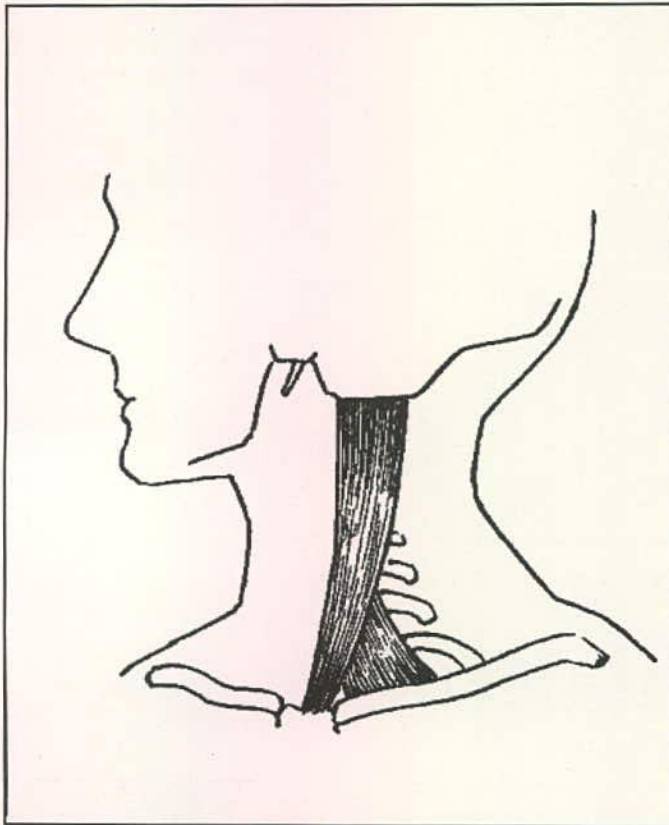


Apply tape base in groove between clavicle and free border of trapezius muscle, almost to acromion.



Extend neck, side bend and rotate away from the taped side. Adhere tape along side of neck to finish.

STERNOCLEIDOMASTOID



ORIGIN

Anterior surface of manubrium sterni.
Sternal 1/3rd of superior anterior surface of clavicle.

INSERTION

Mastoid process; Outer half of superior nuchal line of occipital bone.

NERVE C2, C3

Spinal root of CN XI
(Accessory nerve)

FUNCTION

When the muscle acts unilaterally, it laterally flexes the neck with rotation of the head to opposite side. Bilateral contraction causes neck flexion so that the chin is thrust forward. The muscle may also help in respiration by elevating the sternum.

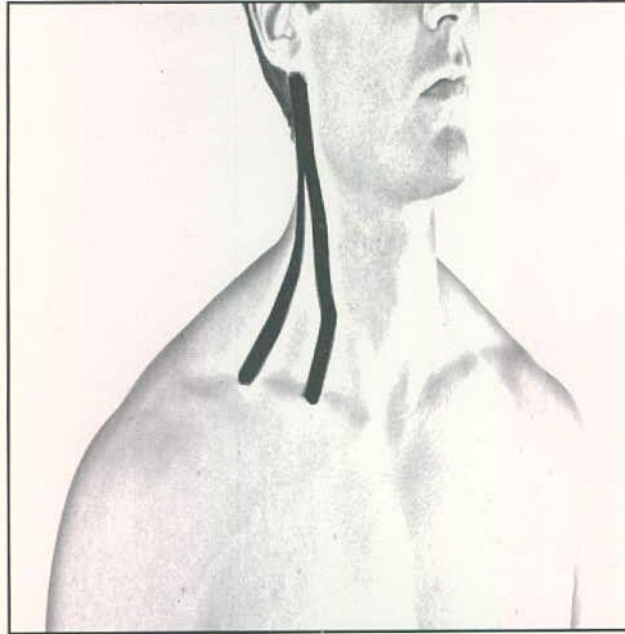
TAPE SPECIFICATIONS

WIDTH 1 in.
LENGTH 6-8 in.
Y-SHAPED TAPE

CLINICAL APPLICATION

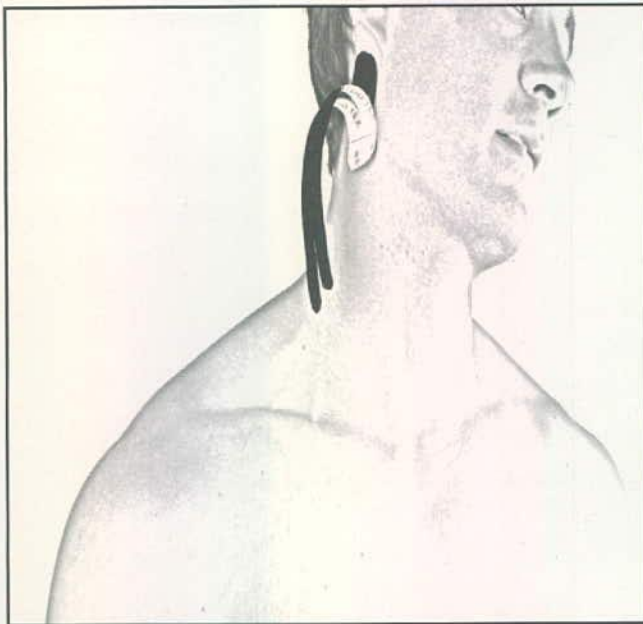
- Torticollis (wry neck).
- Costoclavicular symptoms.

COMPLETED TAPING

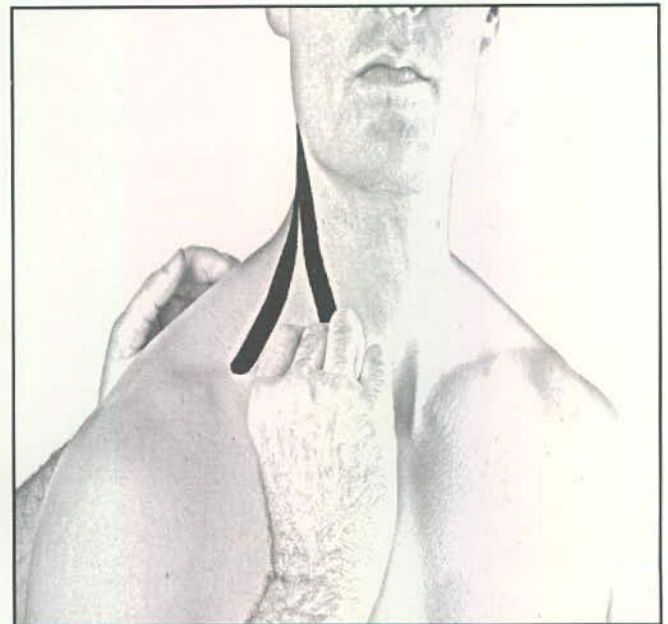


The completed Sternocleidomastoid Taping.

HOW TO ADHERE

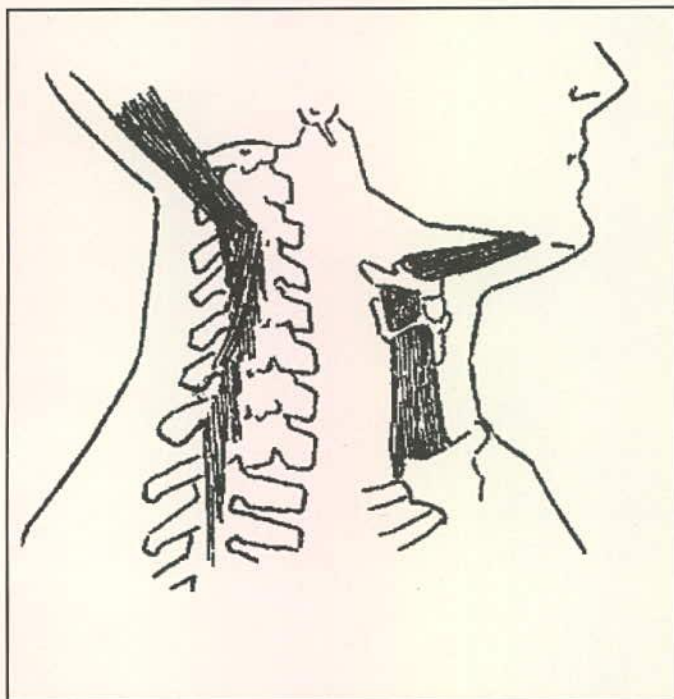


To elongate sternocleidomastoid (SCM), rotate head toward the side to be taped. Place tape base on mastoid process of temporal bone of skull. Apply medial tape tail over sternal head of muscle.



To visualize clavicular head, side bend away from the involved SCM, maintain head rotation to same side. Apply tape over clavicular fibers to finish. Be sure to check whether or not tape is pulling on client's neck.

LONGUS CAPITIS, LONGUS COLLI, STERNOHYOIDEUS, THYROHYOIDEUS



NERVE C1-C6

Spinal nerves, Ansa cervicalis

FUNCTION

Longus capitis and longus colli muscles act bilaterally to flex the neck and head against the pull of the posteriorly located semispinalis and suboccipital muscles which are extensors of the cervical region. If the longus muscles act unilaterally, they will side bend the neck and head to the same side. Longus colli rotates the neck to the opposite side if it acts by itself.

Sternohyoid and thyrohyoid muscles act to stabilize the hyoid bone in swallowing, coughing and speech functions.

TAPE SPECIFICATIONS

WIDTH 1 in.

LENGTH 4 in.

Y-SHAPED TAPE

ORIGIN

LONGUS CAPITIS:

Base of occipital bone.

LONGUS COLLIS:

Anterior tubercle of C1, bodies of C1-C3 vertebrae, transverse processes of C3-C6 vertebrae.

STERNOHYOID:

Posterior surface of manubrium of sternum and medial end of clavicle.

THYROHYOID:

Oblique line of thyroid cartilage.

INSERTION

LONGUS CAPITIS:

Anterior tubercles of C3-C6 transverse processes.

LONGUS COLLI:

Bodies of C5-T3 vertebrae, transverse processes of C3-C5 vertebrae.

STERNOHYOID:

Body of hyoid bone.

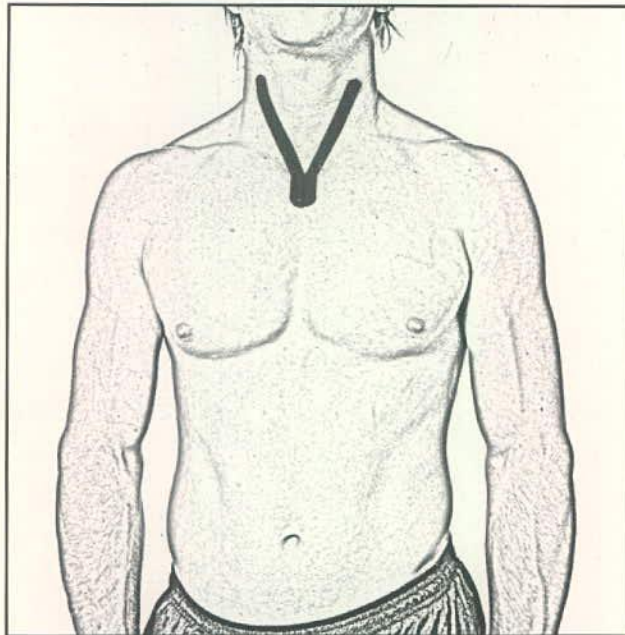
THYROHYOID:

Body of hyoid bone.

CLINICAL APPLICATION

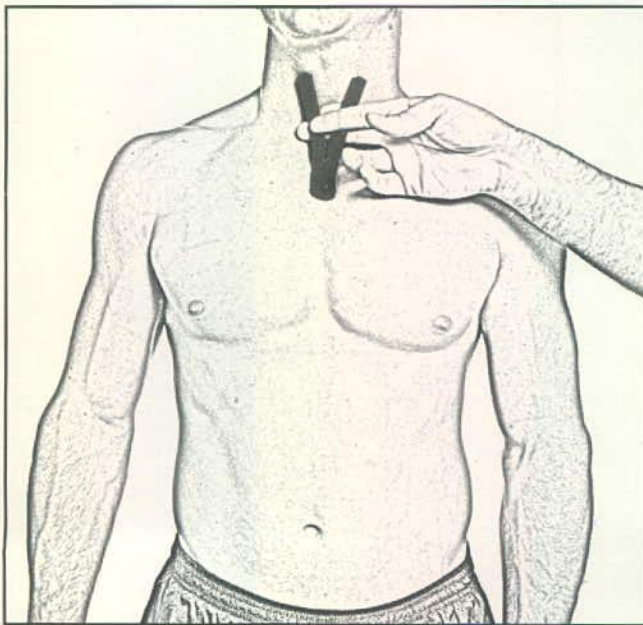
- Chronic torticollis, thoracic outlet syndrome, wryneck.

COMPLETED TAPING

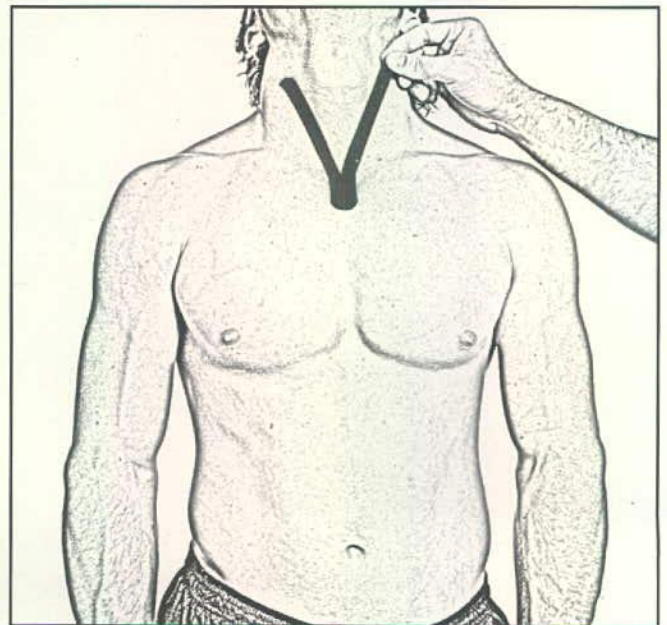


The completed taping in relaxed position.

HOW TO ADHERE

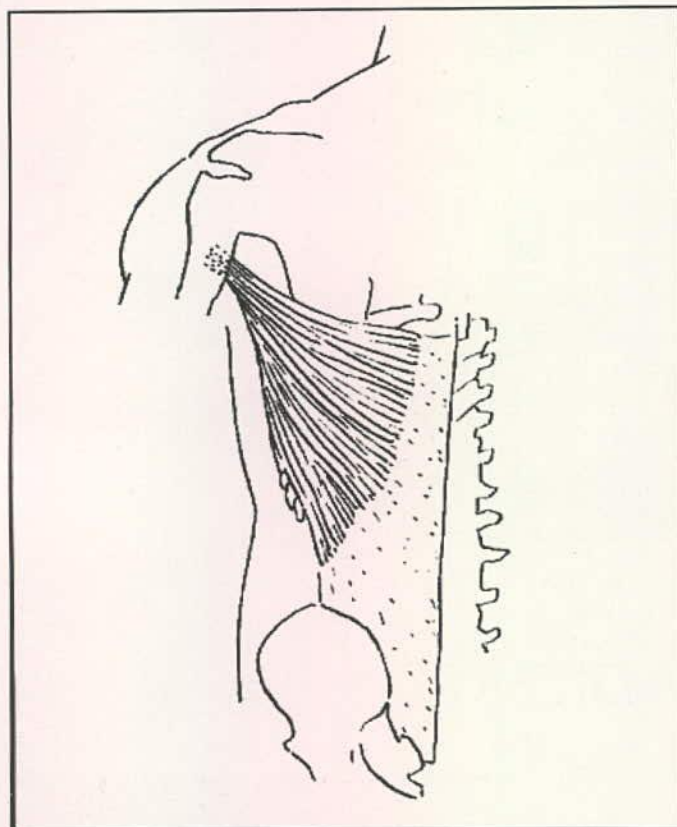


Neck is flexed forward 45°. Apply base of "Y" to manubrium sterni.



Gradually extend neck. At point of maximum extension, adhere the tape.

LATISSIMUS DORSI



ORIGIN

Spinous processes of last 5 or 6 thoracic vertebrae, thoracolumbar fascia, outer lip of iliac crest.

Last 3 or 4 ribs.

Spinous processes of sacrum and inferior angle of scapula.

INSERTION

Posterior lip of bicipital groove of humerus.

NERVE C6 - C8

Thoracodorsal (middle-subscapular) nerve

FUNCTION

Latissimus Dorsi is a large, thin, triangular muscle. From the lower half of the thoracic and lumbar vertebrae, the belly of the muscle gradually becomes thinner, and at the lateral border, it winds medially forward. In both adduction and internal rotation of the shoulder joint, latissimus dorsi has a much stronger action than does the pectoralis major. Latissimus also pulls the humerus and scapula inferiorly. If this action ceases, it is not possible to support the body weight by the upper extremity. It has been suggested that there may be a relationship between latissimus dorsi and the pancreas whereby dysfunctions in this muscle may affect diabetes, hyperinsulinism, hypoglycemia, and other sucrose metabolic diseases. However, this relationship has not been well studied.

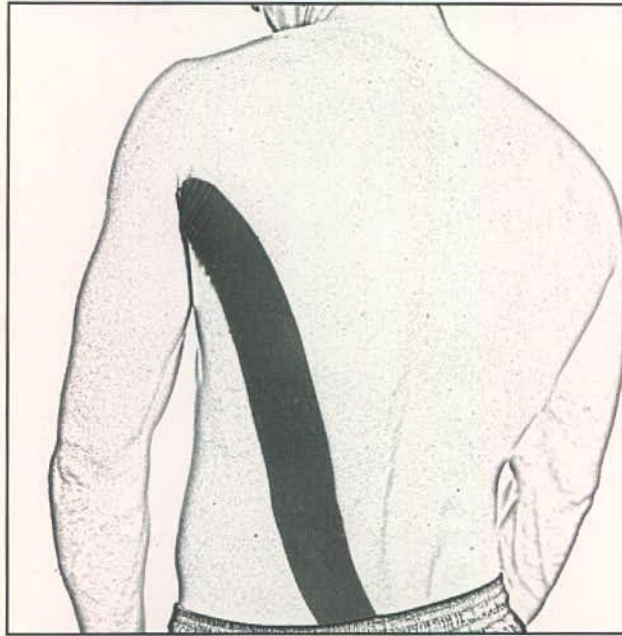
TAPE SPECIFICATIONS

WIDTH 2 in.
LENGTH 16 in.
I-SHAPED TAPE

CLINICAL APPLICATION

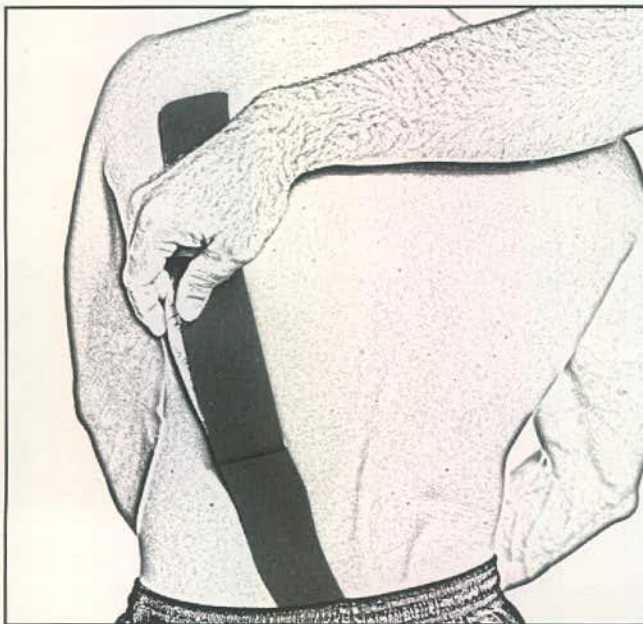
- Thoracic pain, idiopathic scoliosis, frozen shoulder.

COMPLETED TAPING

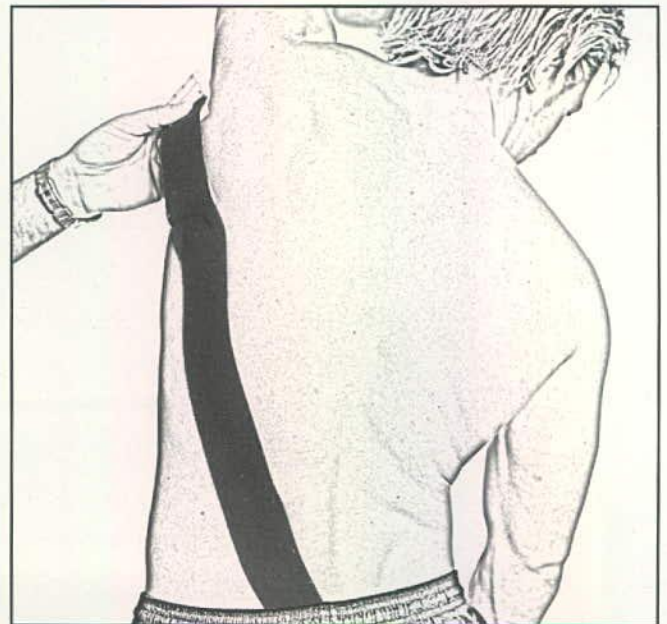


The Latissimus Dorsi Taping in related position.

HOW TO ADHERE

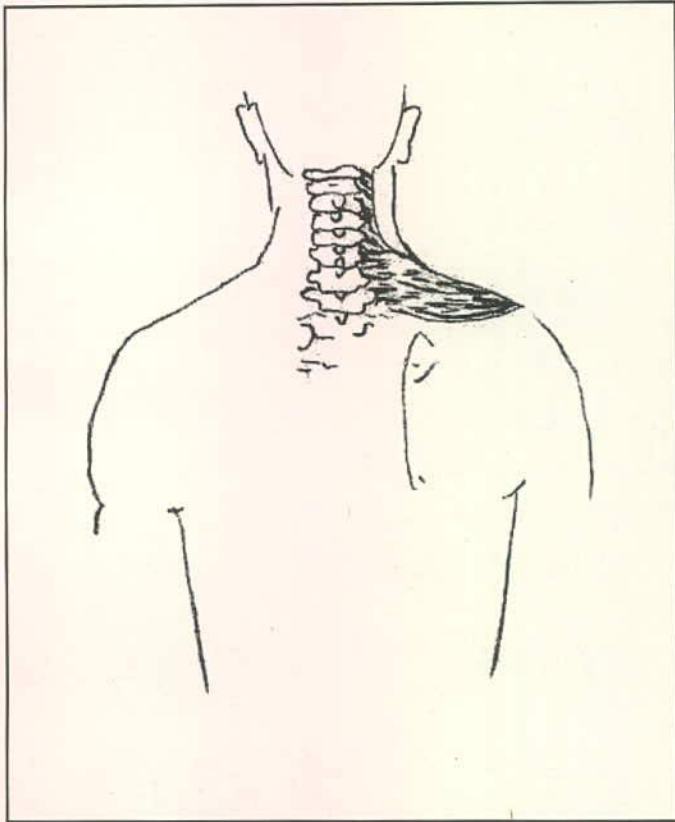


Apply tape base to region of spinous processes of the 3rd to 4th lumbar vertebrae of the involved side. Gradually flex trunk away and apply tape along course of muscle belly.



With elbow extended, fully flex and externally rotate shoulder. Adhere the tape to the lesser tubercle of humerus.

UPPER TRAPEZIUS



ORIGIN

External occipital protuberance, medial 1/3 of superior nuchal line of occipital bone, ligamentum nuchae.

INSERTION

Lateral 1/3 of posterior surface of clavicle.

NERVE C2 - C4

Spinal accessory nerve.

FUNCTION

The trapezius muscle is comprised of 3 parts: the upper, middle, and lower fibers. The upper fibers can be further subdivided into superior and inferior regions. Fibers of the superior region help in raising the upper extremity, while those of the inferior region help to raise the extremity while at the same time act to upwardly rotate and adduct the scapula. When carrying objects, the upper trapezius works to support the distal end of the clavicle and acromion, thus acting as a counterweight.

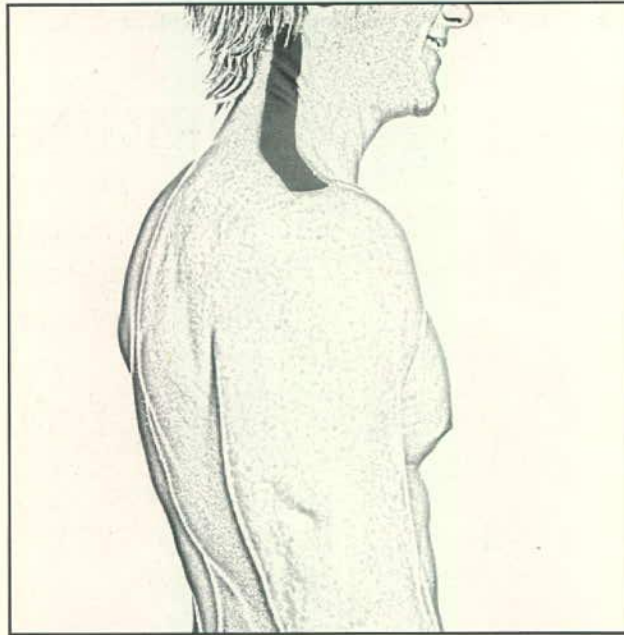
TAPE SPECIFICATIONS

WIDTH 1 in.
LENGTH 9-10 in.
I or Y-SHAPED TAPE

CLINICAL APPLICATION

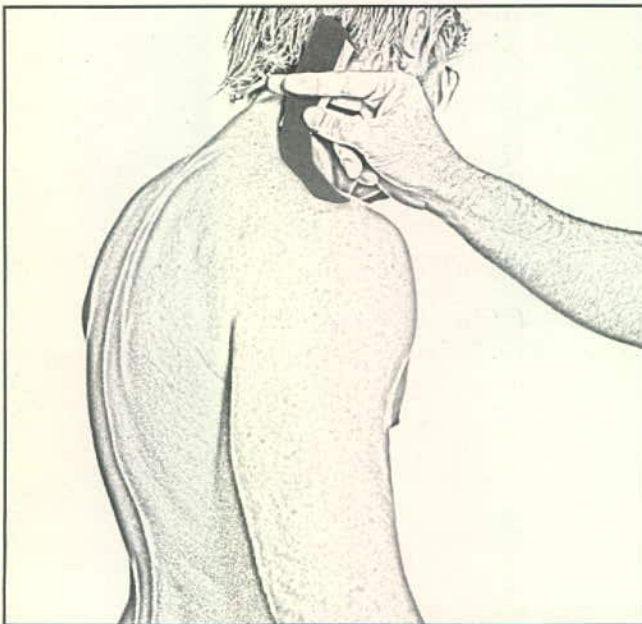
- Cervical disc hernia, cervical and brachial symptoms, stiff shoulder, cervical sprain.

COMPLETED TAPING

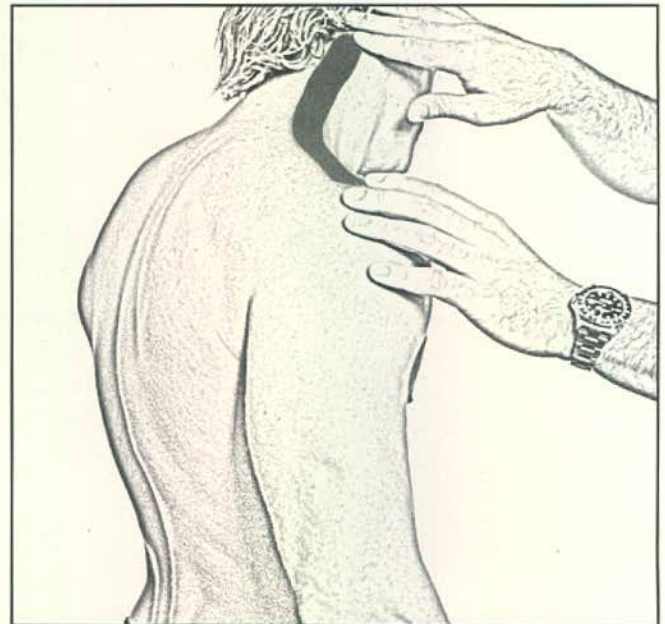


The completed Upper Trapezius Taping in relaxed position.

HOW TO ADHERE

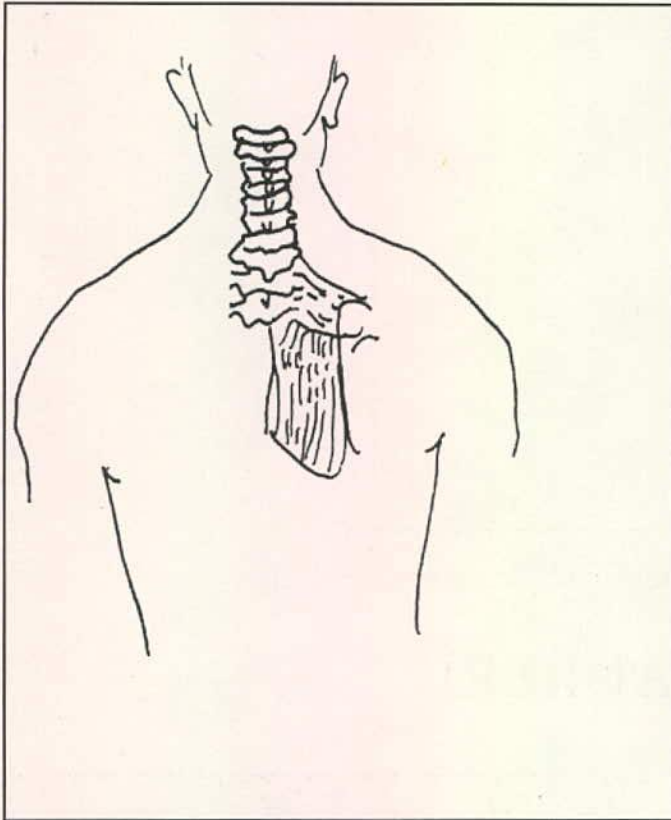


Flex the neck to about 45° and adhere base of tape to skin just below the hair line. Apply other end of tape to acromion while rotating the head toward the involved side.



To relax upper trapezius, adhere base of tape to acromion, rotate head toward the involved side, then apply remainder of tape along course of muscle fibers toward hair line.

MIDDLE TRAPEZIUS



ORIGIN

Posterior longitudinal ligaments. Spinous processes of 7th cervical and upper thoracic vertebrae.

INSERTION

Superior lip of spine of scapula.

NERVE C2 - C4

Spinal accessory nerve.

FUNCTION

The trapezius muscle is comprised of 3 parts: the upper, middle, and lower fibers. The middle trapezius assists in adduction of the scapula. If the middle trapezius becomes weak, then as the upper limb is raised the scapula slides laterally.

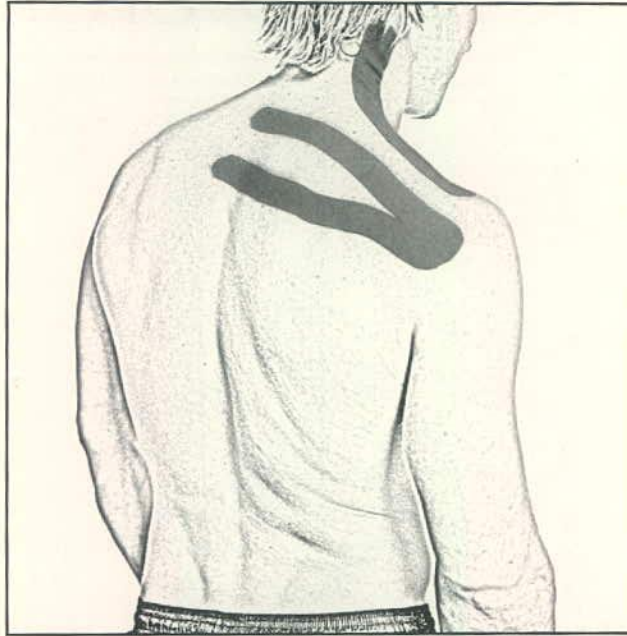
TAPE SPECIFICATIONS

WIDTH 2 in.
LENGTH 10 in.
Y-SHAPED TAPE

CLINICAL APPLICATION

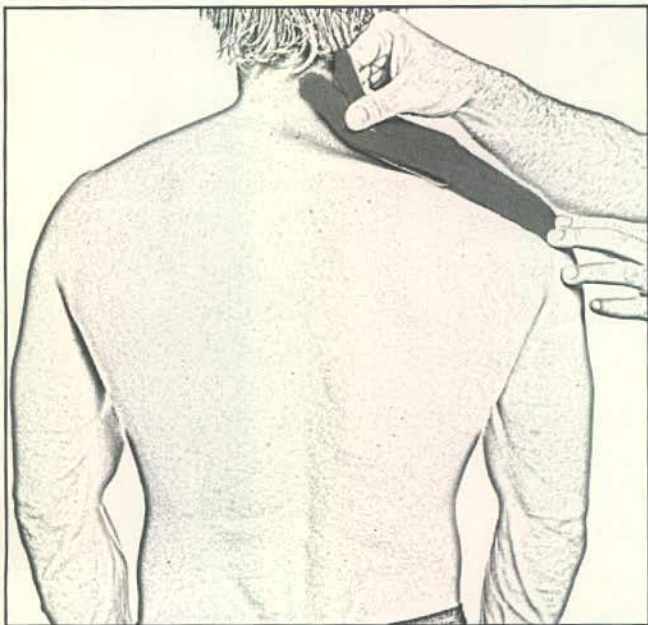
- Cervical disc hernia, cervical and brachial symptoms, stiff shoulder, cervical sprain.

COMPLETED TAPING

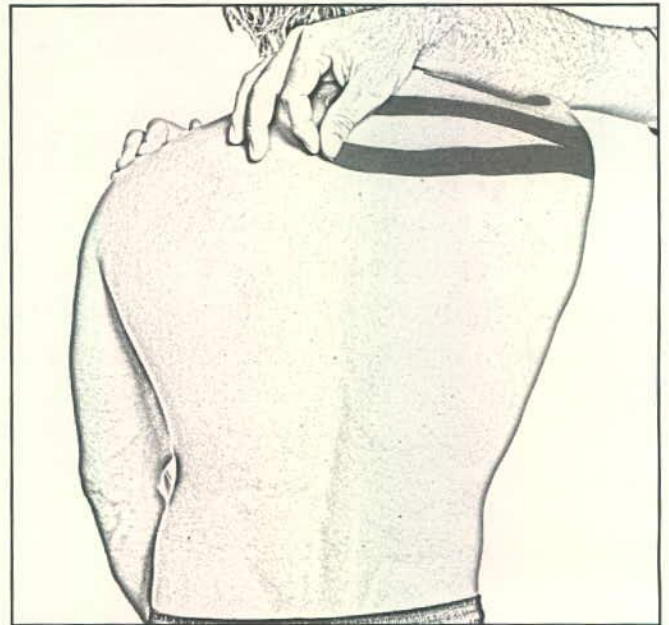


The Completed Upper and Middle Trapezuis Tapings.

HOW TO ADHERE

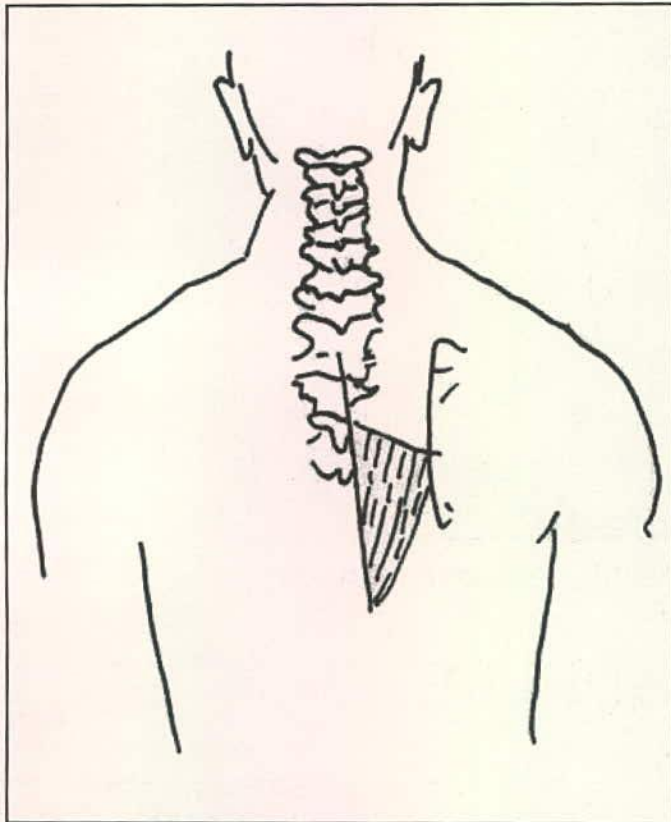


Adhere base of tape posterior to acromion process.



Flex elbow to 90° and raise elbow to shoulder level. Horizontally adduct humerus to front of body and apply tape along course of muscle fibers toward spinous processes of C6 to T3 to finish.

LOWER TRAPEZIUS



ORIGIN

Supraspinous ligaments and spinous processes of lower 7 thoracic vertebrae.

INSERTION

Upper border and tuberosity at base of spine of scapula.

NERVE C2 - C4

Spinal accessory nerve.

FUNCTION

The trapezius muscle is comprised of 3 parts: the upper, middle, and lower fibers. The lower trapezius assists in upward rotation of the scapula, but it also depresses and adducts the scapula. When the lower trapezius is not working, the scapula is not stabilized and there is not sufficient upward rotation of the glenoid for full flexion of the humerus.

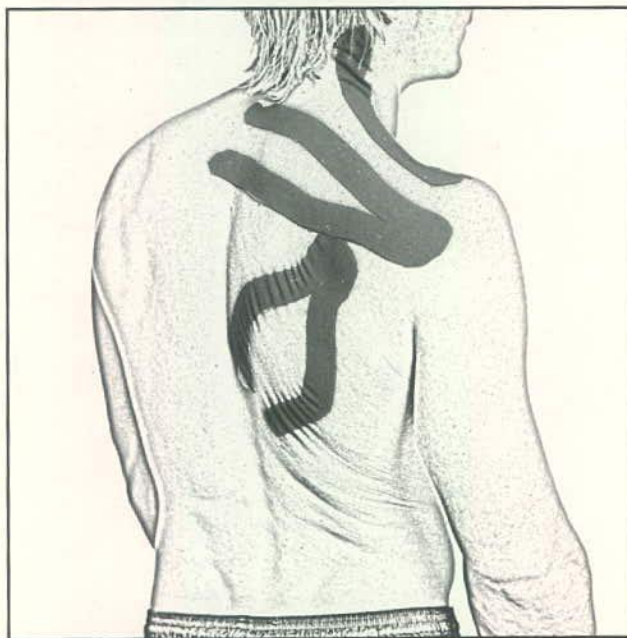
TAPE SPECIFICATIONS

WIDTH 2 in.
LENGTH 12 in.
Y-SHAPED TAPE

CLINICAL APPLICATION

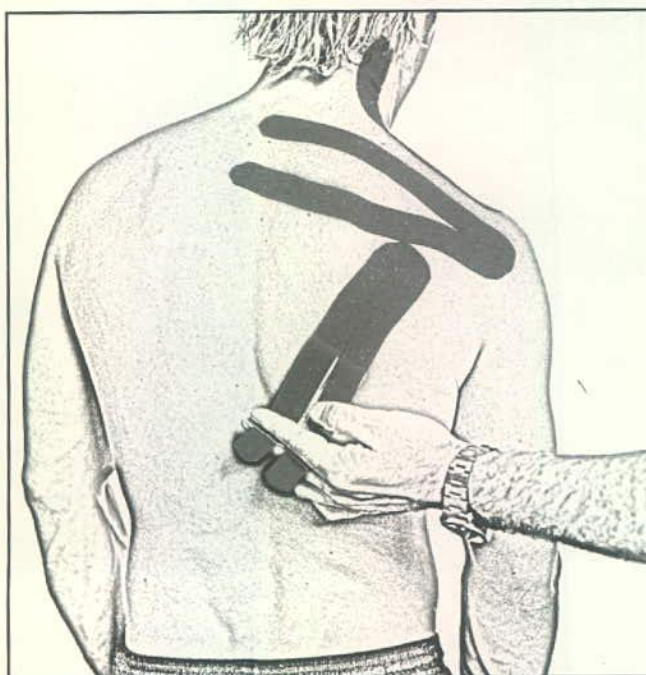
- Cervical disc hernia, cervical and brachial symptoms, stiff shoulder, cervical sprain.

COMPLETED TAPING

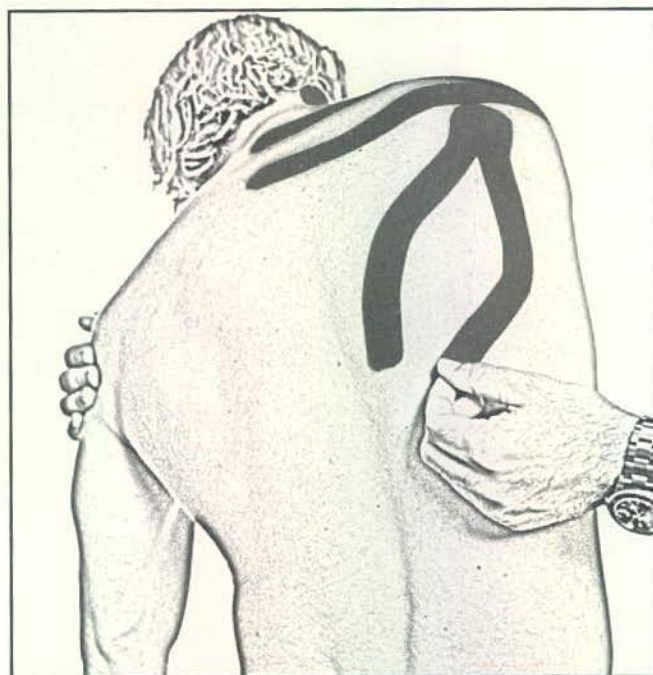


The completed Upper, Middle, and Lower Trapezius Tapings.

HOW TO ADHERE

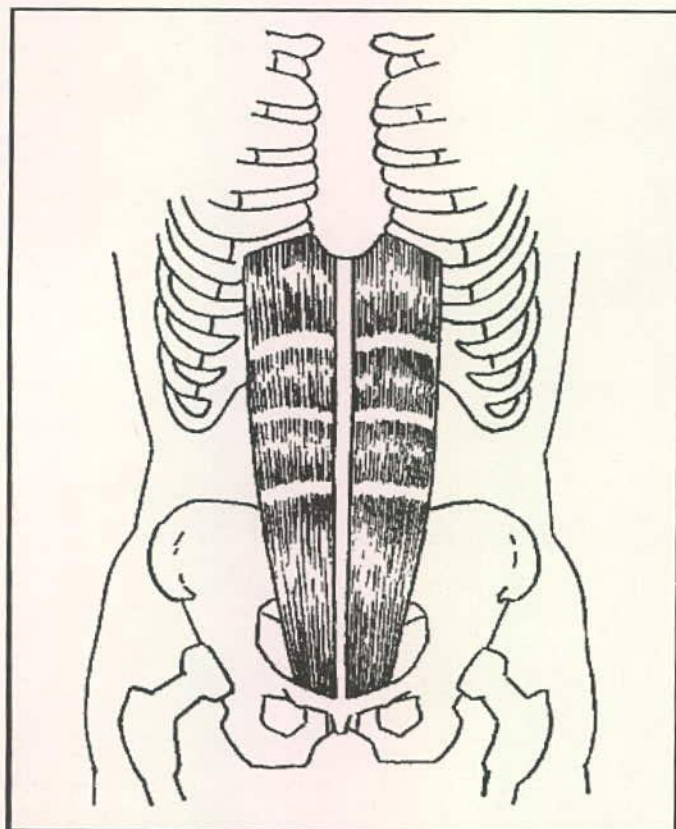


Fix base of tape on the medial end of the spine of the scapula. Fully extend the shoulder and retract scapula.



Apply the end of upper tape tail at T4 level of of vertebral column and that of lower tape tail at T12 spinous process. Then adduct arm across front of body, and side bend upper turnk to opposite side to affixed tape tails.

RECTUS ABDOMINIS



ORIGIN

Crest of pubis.
Symphysis of pubis.

INSERTION

Xyphoid process, 5th-6th costal cartilages.

NERVE C5 - T12

FUNCTION

The rectus abdominis anteriorly flexes the thoracic lumbar spine. When one side is involved in movement, it helps in side flexion of the vertebral column. When the head is raised and when standing straight as in good posture, this muscle becomes active. It also functions to compress the abdominal contents. If the rectus abdominis is weak, the lower back becomes tired and frequently pain or aching is felt. When only one side is weak, the movement of the shoulder on the opposite side becomes less active and more difficult to move. In many cases during pregnancy, suppleness and elasticity of the muscle are lost with subsequent difficulties experienced in childbirth.

The transversus abdominis helps the rectus abdominis during trunk flexion, and also in compressing the abdominal viscera during the expiration phase of respiration.

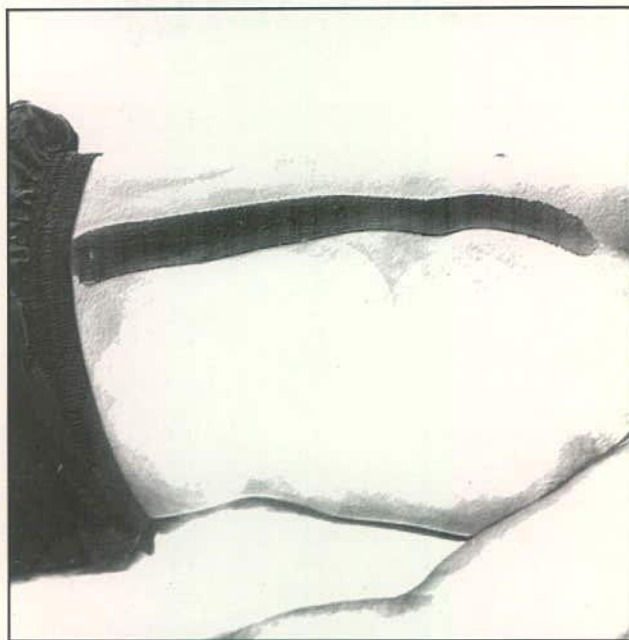
TAPE SPECIFICATIONS

WIDTH 2 in.
LENGTH 10 in.
I-SHAPED TAPE

CLINICAL APPLICATION

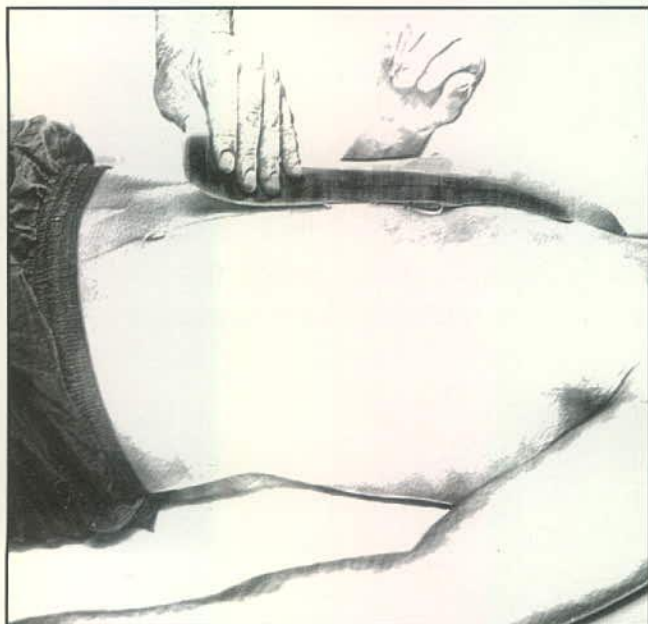
- Spinal stenosis spondylolysis, spondylolisthesis.

COMPLETED TAPING

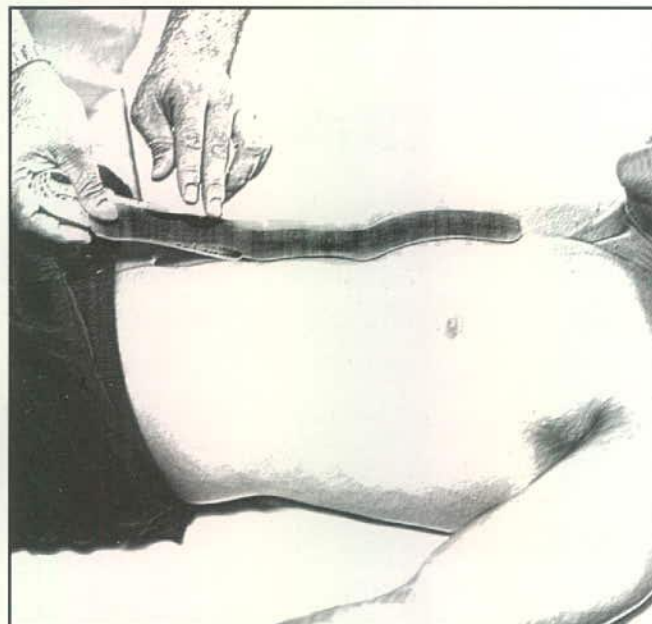

The Completed Rectus Abdominis Taping.

HOW TO ADHERE

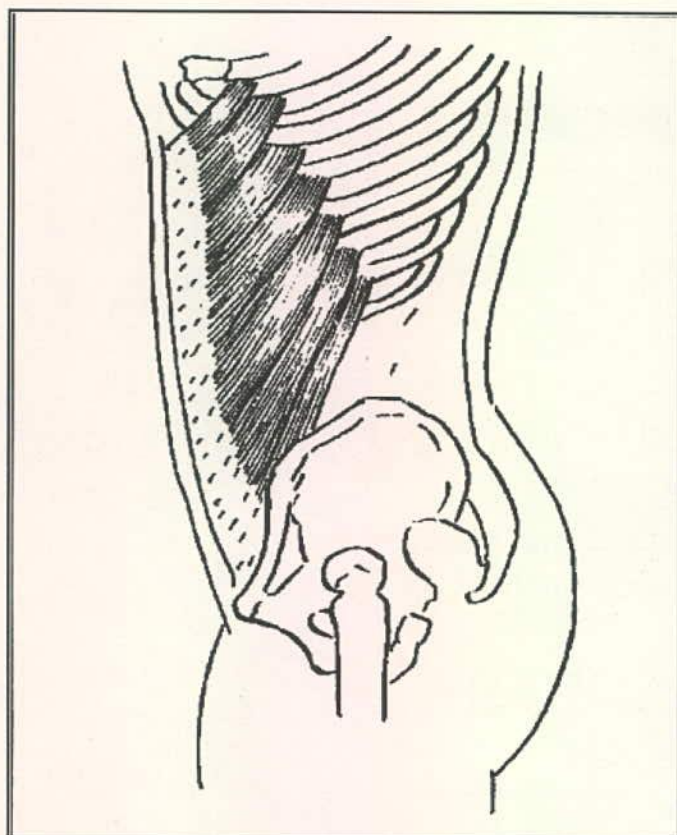


Raise the head and flex both knees.
Adhere tape from xiphoid process,
5th-6th costal cartilages with 20% stretch.



As legs are gradually lowered and
stretched with continued neck flexion,
adhere tape near the symphysis pubis.

EXTERNAL ABDOMINIS OBLIQUE



ORIGIN

Lower anterior surface of 5th-12th ribs.

INSERTION

Linea alba.

Anterior spine and iliac crest.

NERVE T7 - T12

Subcostal nerve.

FUNCTION

The two external abdominis oblique muscle fibers run downward and medially's together they cooperate in flexing the trunk by resisting each other. When the fibers of one side act, the result is lateral flexion and rotation of the trunk to the opposite side.

TAPE SPECIFICATIONS

WIDTH 2 in.

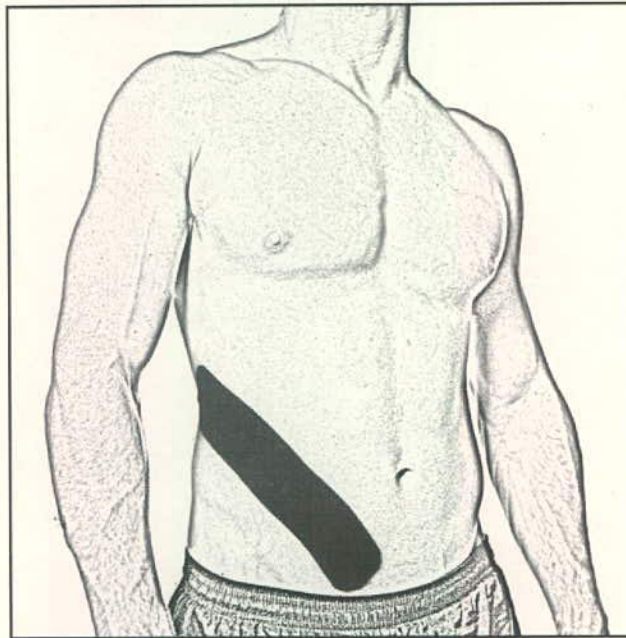
LENGTH 8 in.

I, Y, or FAN-SHAPED TAPE

CLINICAL APPLICATION

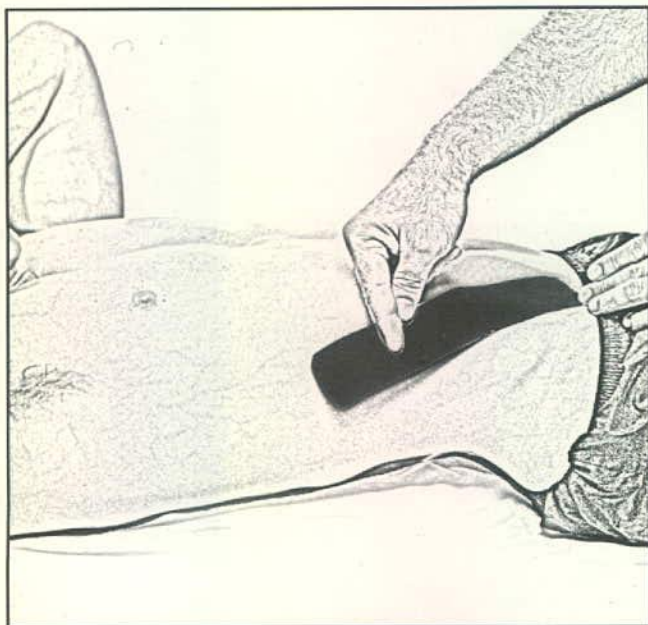- Lumbago, lumbar disc hernia, ossifying costal cartilage, colitis.

COMPLETED TAPING

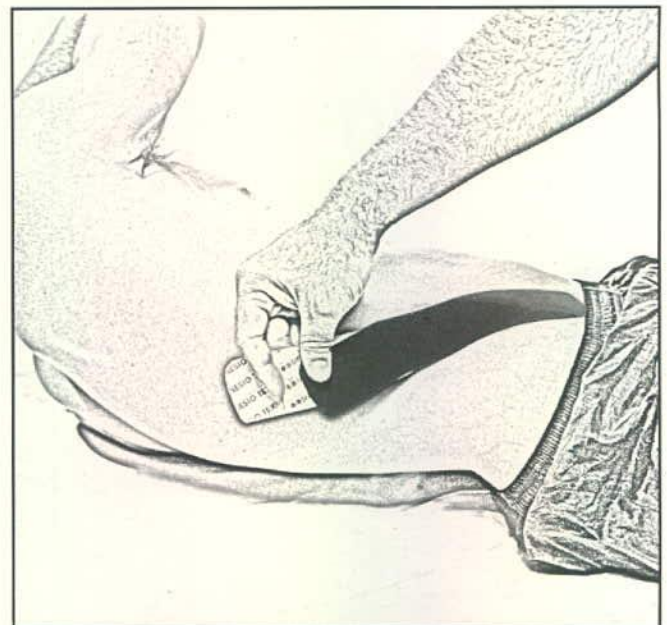


The Completed External Abdominis Oblique Taping.

HOW TO ADHERE

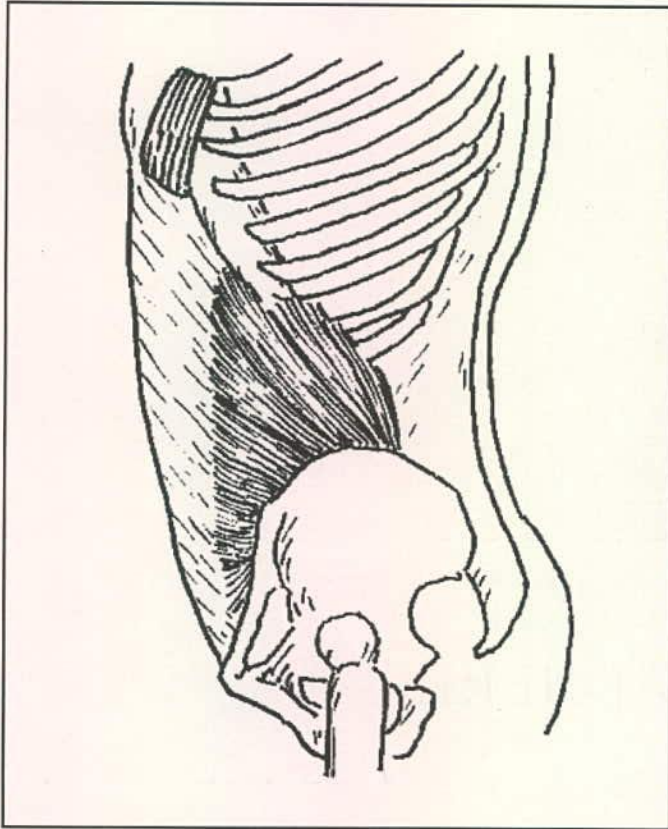


Adhere base of the tape below the navel in the region of the anterior superior iliac spine (ASIS). Gradually rotate trunk away from the side of involvement.



Apply the tape along the course of the muscle to affix below and lateral to xiphoid process to finish.

INTERNAL ABDOMINIS OBLIQUE



ORIGIN

Iliac fascia deep to lateral posterior of inguinal ligament.

Anterior half of crest of ilium.

Lumbar fascia.

INSERTION

Crest of pubis, medial part of pectineal line.

Linea alba by aponeurosis.

Inferior border of 10-12th ribs.

NERVE T6-L1

Iliohypogastric nerve

FUNCTION

The internal abdominis oblique runs in 3 directions, and helps in flexion of the lumbar spine and in rotation of the spine to the same side. This muscle is mainly concerned in active rotation of the spinal column.

TAPE SPECIFICATIONS

WIDTH 2 in.

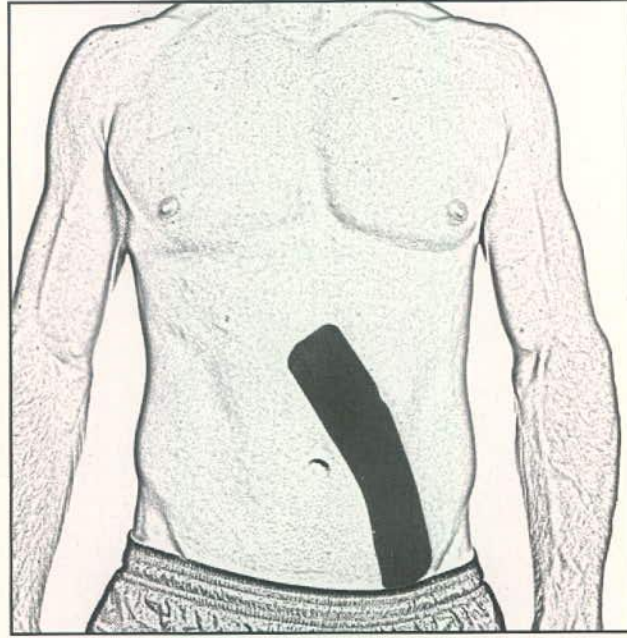
LENGTH 8 in.

I-SHAPED TAPE

CLINICAL APPLICATION

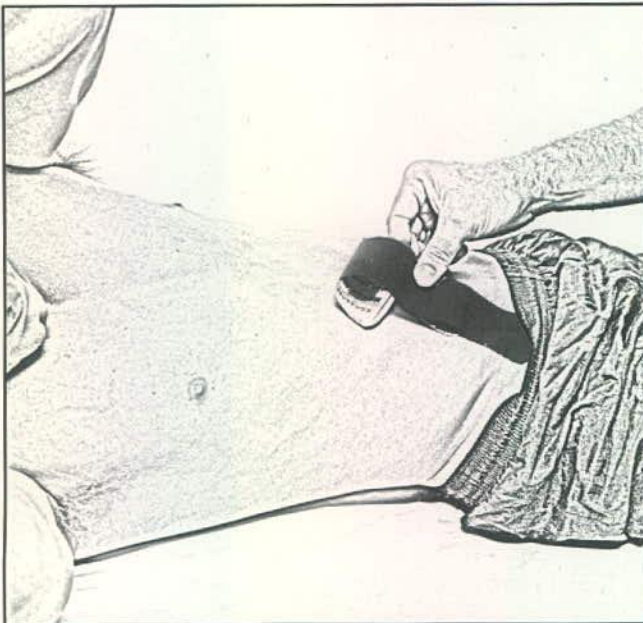
- Lumbago, lumbar disc hernia, ossifying costal cartilage, lumbar disc hernia.

COMPLETED TAPING

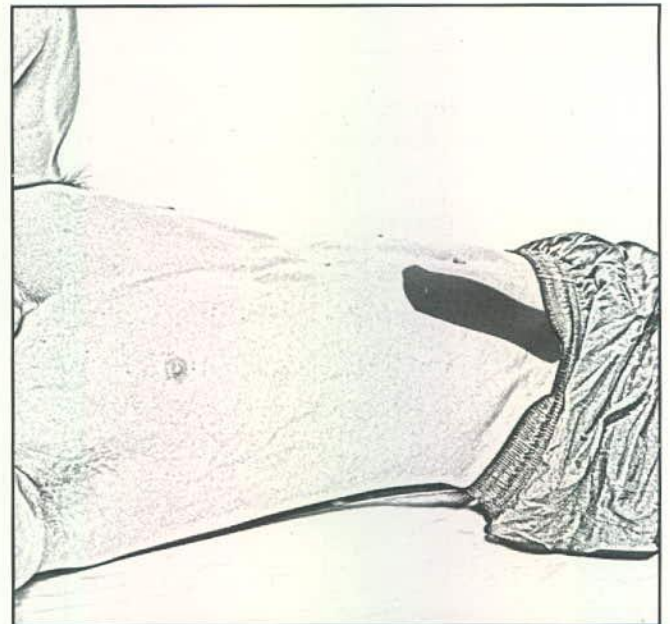


The Completed Internal Abdominis Oblique Taping.

HOW TO ADHERE

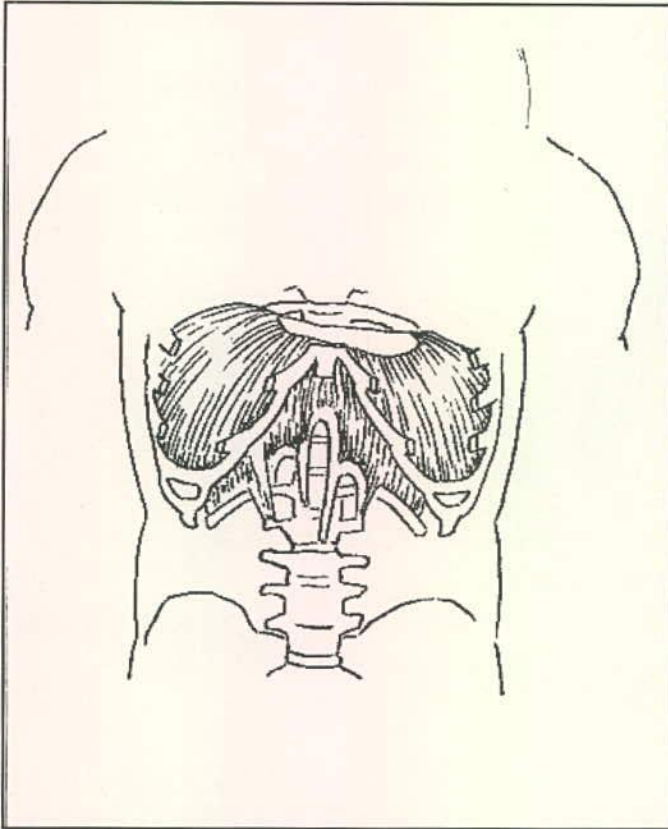


With trunk flexed, rotate trunk towards involved side. Adhere base of tape to region of anterior superior iliac spine (ASIS).



While derotating trunk and lowering into supine position, apply tape along course of muscle to finish.

DIAPHRAGM ANTERIOR



ORIGIN

STERNAL SECTION:

Dorsum of xyphoid process.

COSTAL SECTION:

Inner surface of lower 6 costal cartilages and lower 6 ribs on either side, interdigitating with the transversus abdominis.

LUMBAR SECTION:

Bodies of upper lumbar vertebrae and by 2 fibrous arches on either side which span from the vertebrae to the transverse processes.

INSERTION

Central tendon of the diaphragm.

NERVE C3 - C5

Phrenic nerve.

FUNCTION

The diaphragm is a thin, dome-shaped muscle which separates the chest from the abdominal cavity by its skeletal attachments to the sternum, ribs and lumbar vertebrae.

In the center of the diaphragm is the central tendon in the shape of an inverted "V" and into which insert all of the diaphragmatic muscle fibers.

When the diaphragm contracts, the abdominal viscera are compressed and a negative pressure is formed in the thoracic cavities. This results in the inspiratory phase of respiration. Expiration occurs when the diaphragm relaxes. The lower ribs expand to allow deep breathing.

When diaphragmatic muscle imbalance occurs, the diaphragm will be either raised or lowered. This in turn may be related to such complicated symptoms as hiccups, breathing difficulties, visceroptosis, and may also be associated with angina pectoris.

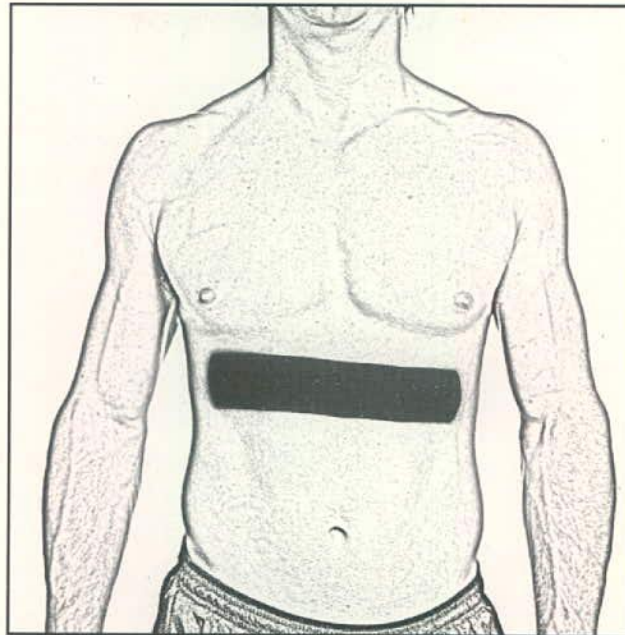
TAPE SPECIFICATIONS

WIDTH 2 in.
LENGTH 10-12 in.
I-SHAPED TAPE

CLINICAL APPLICATION

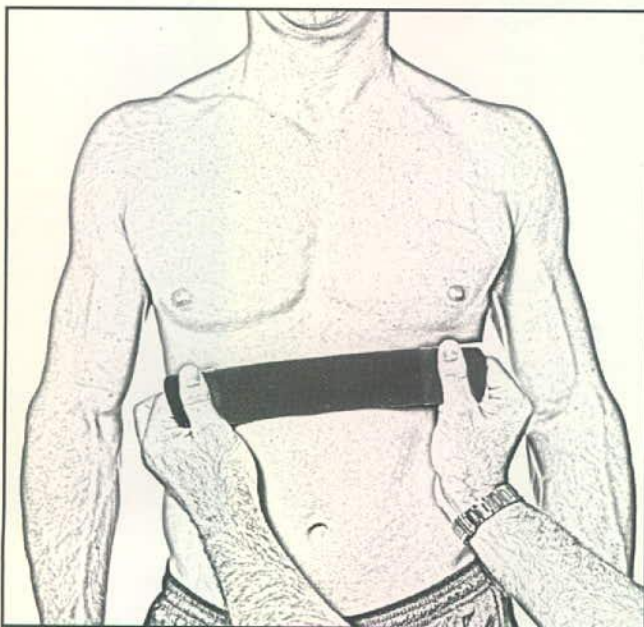
- Elevated diaphragm with increased intrathoracic pressure, angina pectoris, stomach ache.

COMPLETED TAPING

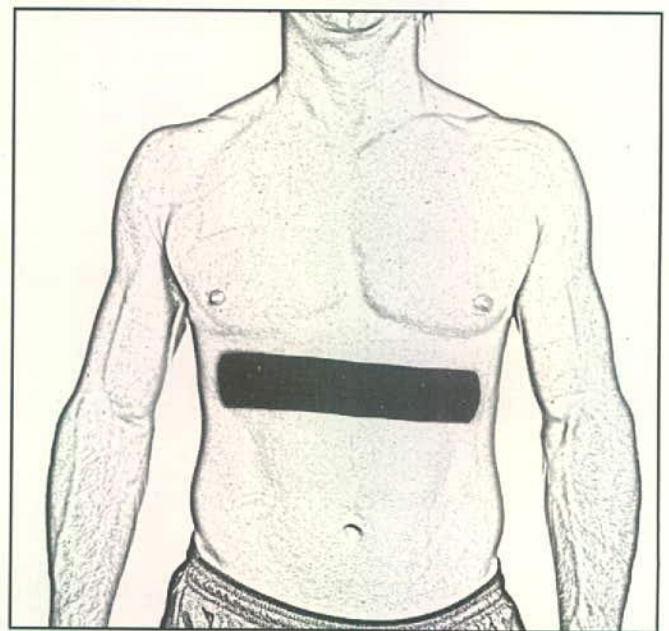


The Completed Diaphragm Anterior Taping.

HOW TO ADHERE

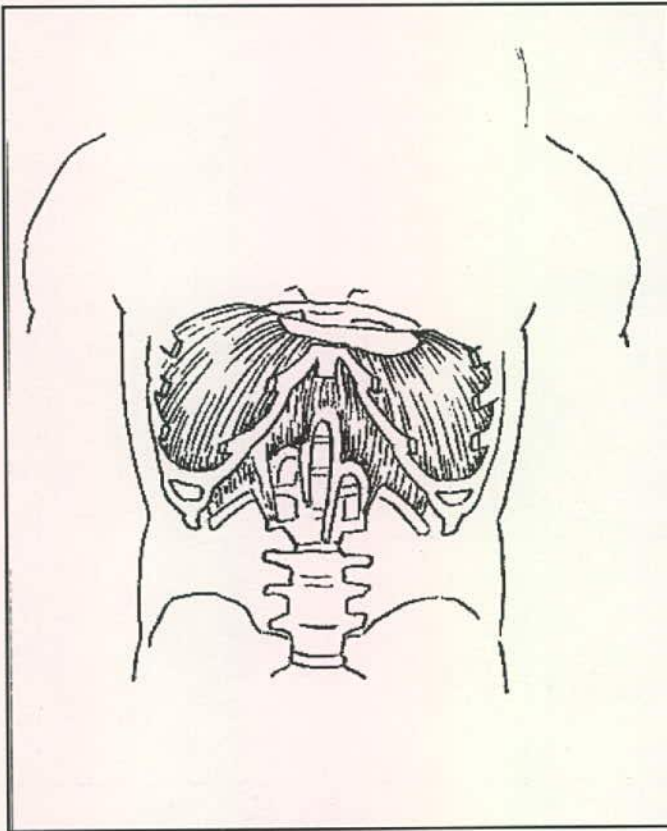


Either standing or seated, breathe out, contract the abdominal muscles to pull in the abdomen. Adhere the base of about 2-3 in. of the tape about 1 inch below the xyphoid process.



Gradually take in a deep breath to expand the lower ribs and hold. Affix tape tails at the point of maximum rib cage expansion.

DIAPHRAGM POSTERIOR



ORIGIN

STERNAL SECTION:

Dorsum of xyphoid process.

COSTAL SECTION:

Inner surface of lower 6 costal cartilages and lower 6 ribs on either side, interdigitating with the transversus abdominis.

LUMBAR SECTION:

Bodies of upper lumbar vertebrae and by 2 fibrous arches on either side which span from the vertebrae to the transverse processes.

INSERTION

Central tendon of the diaphragm.

NERVE C3-C5

Phrenic

FUNCTION

The diaphragm is a thin dome-shaped muscle which separates the chest from the abdominal cavity by its skeletal attachments to the sternum, ribs and lumbar vertebrae.

In the center of the diaphragm is the central tendon in the shape of an inverted "V" and into which insert all of the diaphragmatic muscle fibers.

When the diaphragm contract, the abdominal viscera are compressed and a negative pressure is formed in the thoracic cavities. This results in the inspiratory phase of respiration. Expiration occurs when the diaphragm relaxes. The lower ribs expand to allow deep breathing.

When diaphragmatic muscle imbalance occurs, the diaphragm will be either raised or lowered. This in turn may be related to such complicated symptoms as hiccups, breathing difficulties, visceroptosis, and may also be associated with angina pectoris.

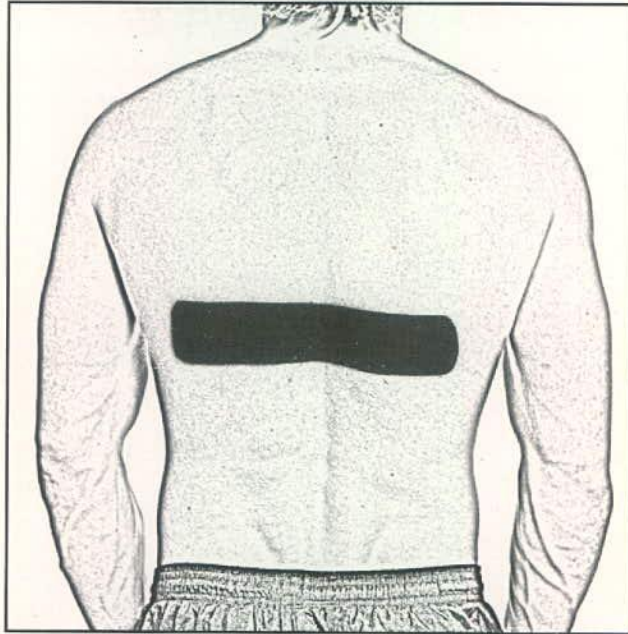
TAPE SPECIFICATIONS

WIDTH 2 in.
LENGTH 10-12 in.
I-SHAPED TAPE

CLINICAL APPLICATION

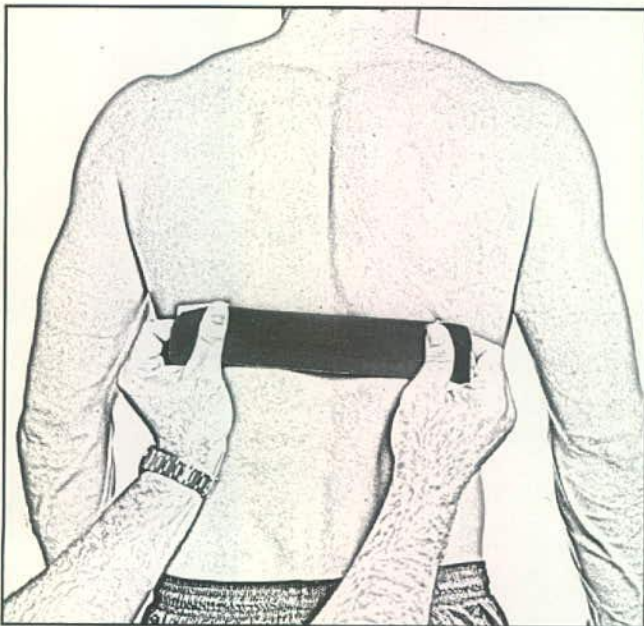
- Visceroptosis, mid-back ache.

COMPLETED TAPING

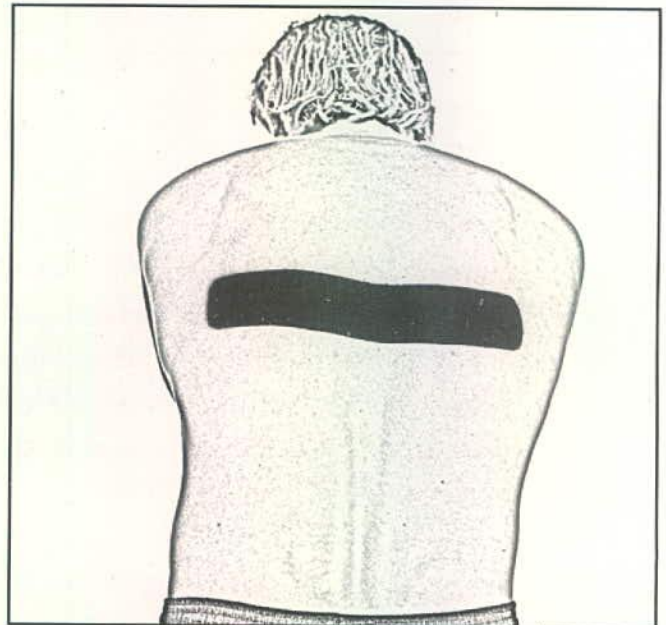


The Completed Diaphragm Posterior Taping.

HOW TO ADHERE

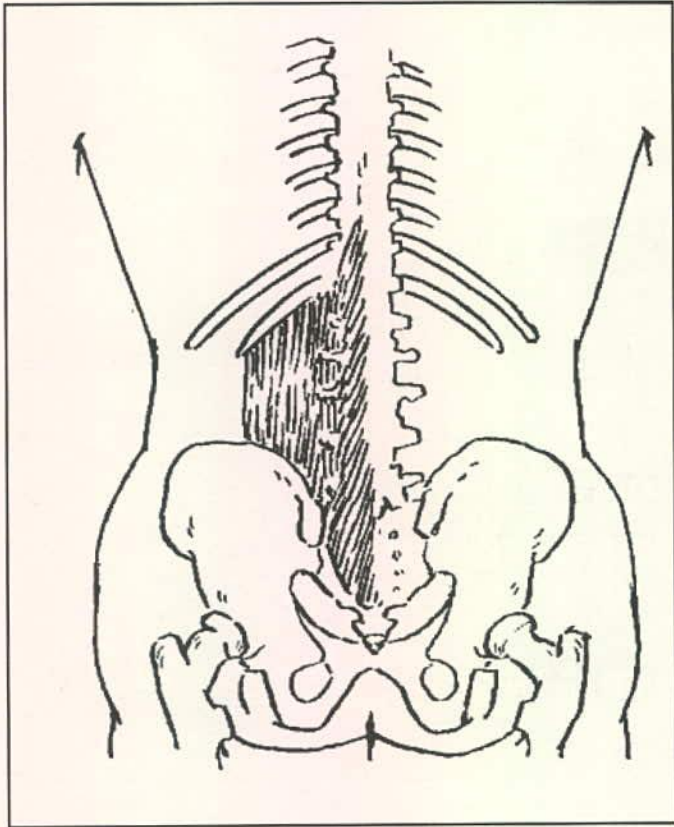


With patient standing, arms fully extended and scapulae retracted so as to narrow the space around the 12th thoracic vertebra. Adhere base of about 2-3 inches of the tape to spinous process of T12.



Gradually take in a deep breath to expand the lower ribs and hold. Bend body slightly forward and adduct both arms to open the posterior section of the lower rib cage. Affix tape at the point of maximum rib cage expansion.

ERECTOR SPINAE



ORIGIN

Common origins of the erector spinae muscle group are the posterior sacrum, iliac crest, sacrotuberous ligament, dorsal sacroiliac ligament, spinous processes of T11-L5 vertebrae and their interspinous ligaments, and thoracolumbar aponeurosis.

INSERTION

Angles of ribs, transverse processes of superiorly located vertebrae.

NERVE

Dorsal branch of spinal nerve.

FUNCTION

The erector spinae muscle group is comprised of three large muscles: iliocostalis, longissimus, and spinalis. Their overall function is to extend the vertebral column which is of major importance in maintenance of upright posture and the ability to move the body forward. The iliocostalis is the most laterally located, followed by the longissimus and the spinalis most medially. Iliocostalis and longissimus also laterally bend the trunk. Superior fibers of longissimus and spinalis also extend the head.

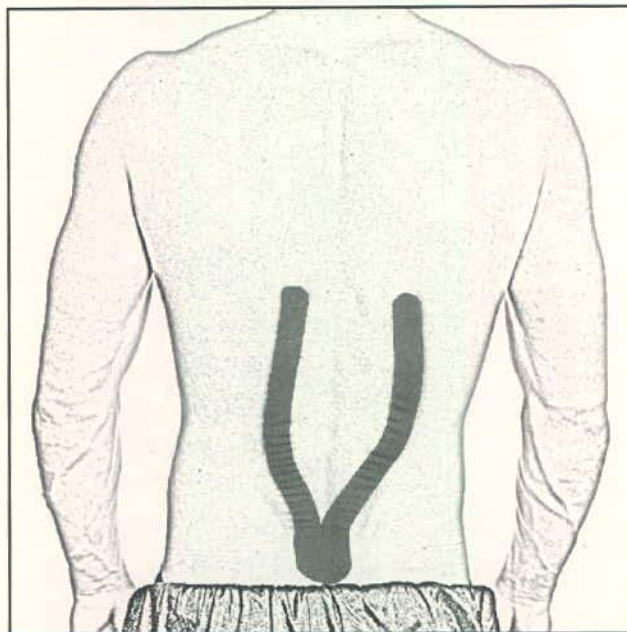
TAPE SPECIFICATIONS

WIDTH 2 in.
LENGTH 11 in.
Y-SHAPED TAPE

CLINICAL APPLICATION

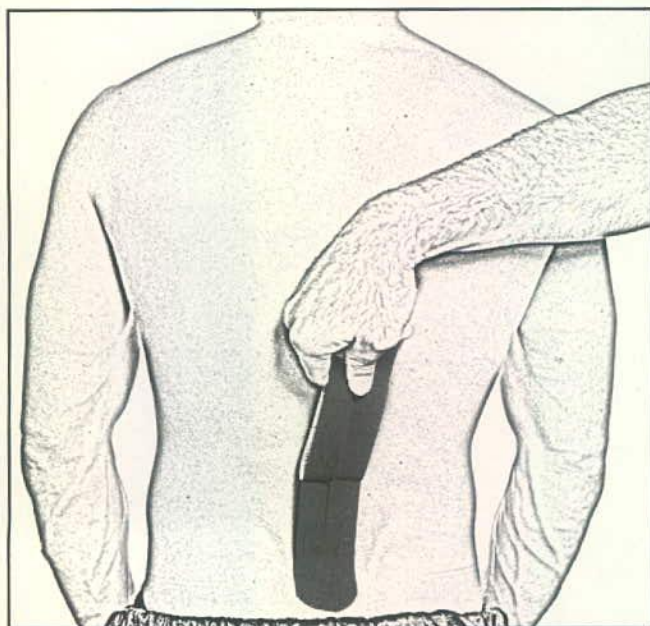
- Lumbar pain symptoms (myofascial pain syndrome), lumbar disc hernia, lumbar deformation, inflammation of floating ribs. Application can be utilized on a bilateral basis.

COMPLETED TAPING

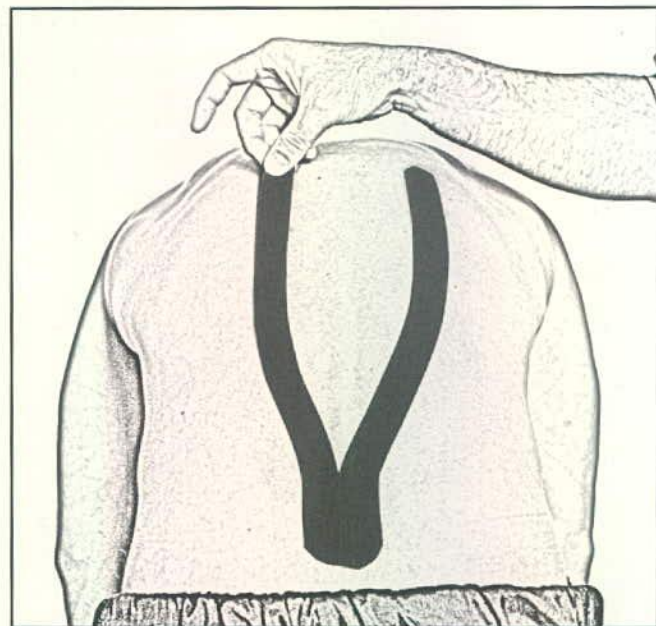


The Completed Erector Spinae Taping.

HOW TO ADHERE



With patient standing, adhere the base of the tape over the sacrum. As client gradually bends forward, apply one of the tape tails along the course of the muscle.



Keeep approximately 5-10° separation between tails of tape. Apply 2nd tape tail in the same manner along the course of the muscle to finish.

PELVIC GIRDLE

Gluteus Maximus

Gluteus Medius & Minimus

Tensor Fascia Lata

Sartorius

Adductors

Piriformis

Quadriceps Femoris

Hamstrings

Soleus, Gastrocnemius

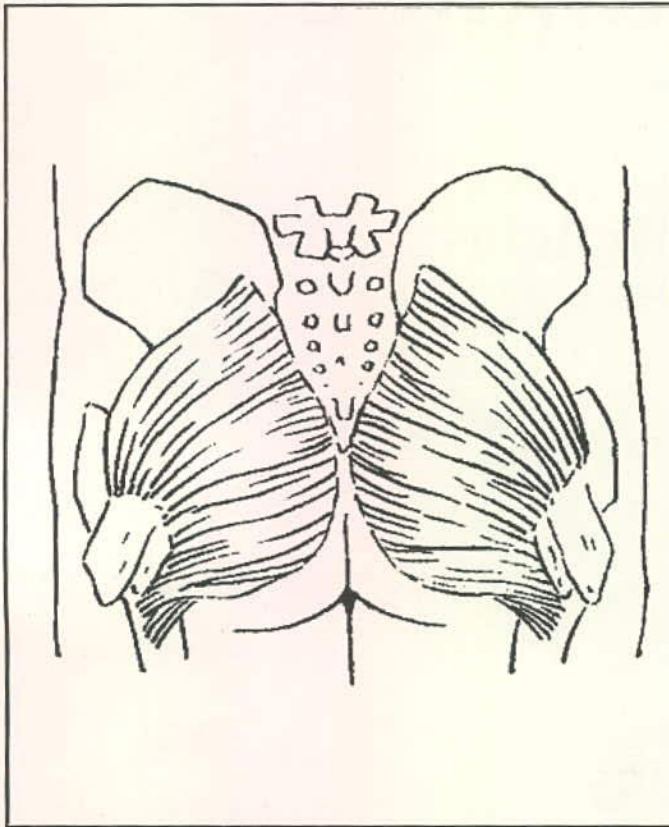
Extensor Hallucis Longus

Peroneus Longus and Brevis

Flexor Hallucis Brevis

Sciatic Nerve Tape

GLUTEUS MAXIMUS



ORIGIN

Ilium behind posterior gluteal line.
Posterior surface of sacrum and coccyx.
Sacrotuberous ligament.

INSERTION

Iliotibial band of fascia lata.
Gluteal ridge of femur.

NERVE L5, S1, S2

Inferior gluteal nerve.

FUNCTION

The gluteus maximus is an extensor of the buttocks; it also functions as a strong external rotator of the femur. The upper 1/3 of the muscle may be used for abduction and the lower 2/3 function to adduct the femur. Thus, this muscle extends (approximately 15°), adducts (20°), externally rotates (approximately 45°) and slightly abducts the thigh. The gluteus maximus is especially active when it is used to rise from a sitting position or when climbing stairs.

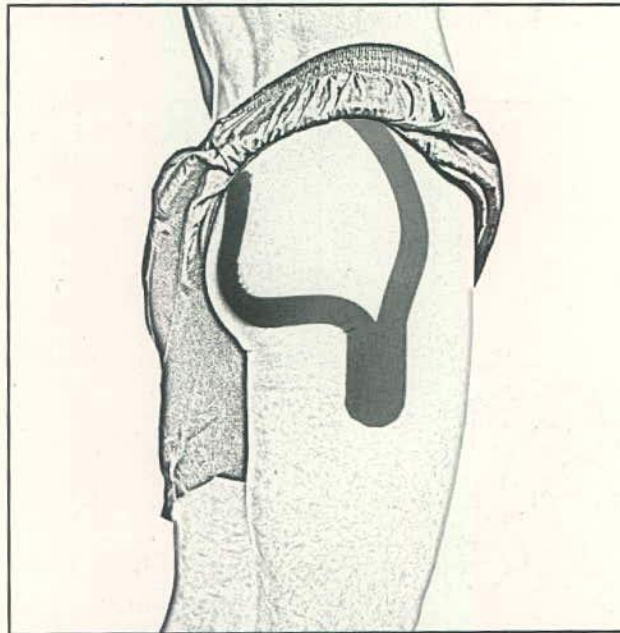
TAPE SPECIFICATIONS

WIDTH 2 in.
LENGTH 12 in.
Y-SHAPED TAPE

CLINICAL APPLICATION

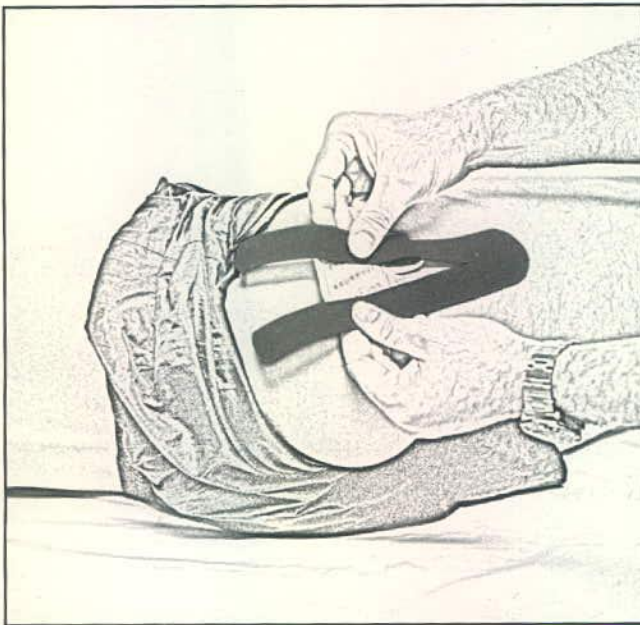
- Lumbago, sciatica, coxitis (inflammation of hip joint), inflammation of sacro-iliac joint.

COMPLETED TAPING

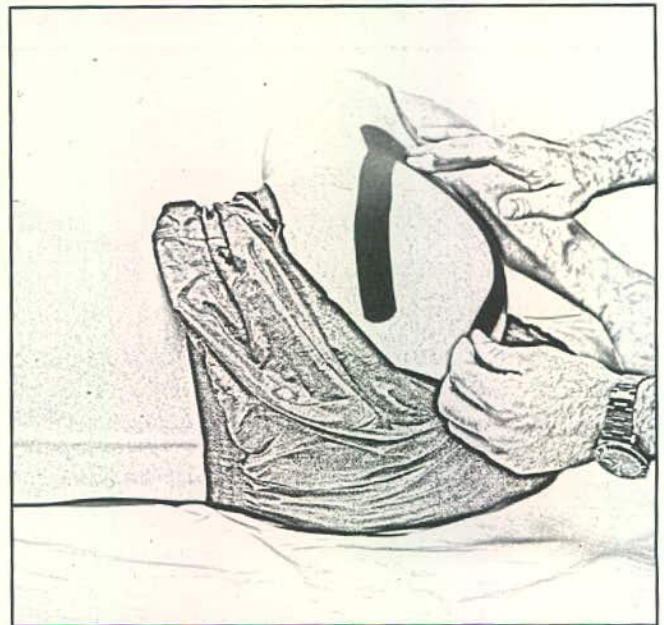

The Completed Gluteus Maximus Taping.

HOW TO ADHERE

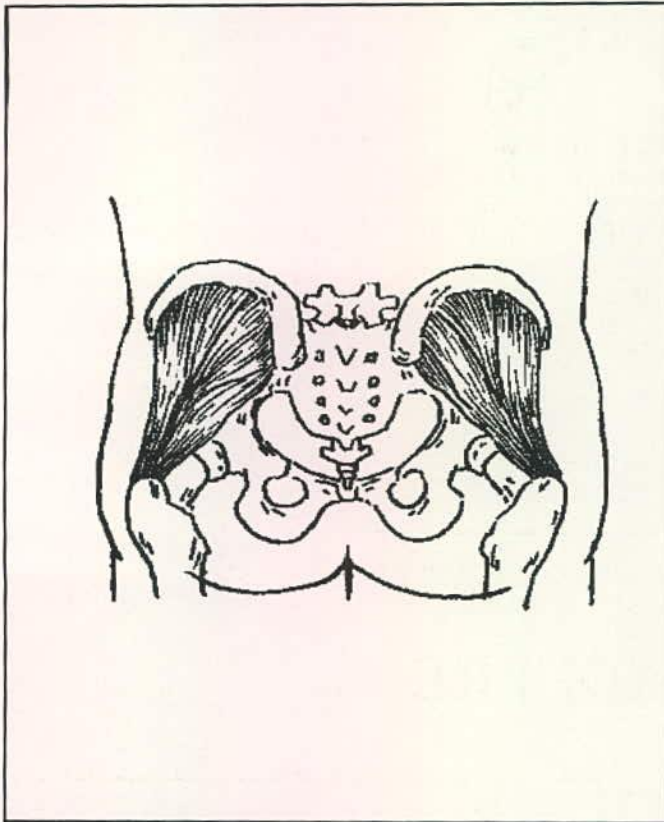


With patient in sidelying, place base of tape with point of "Y" at greater trochanter. Abduct thigh and adhere anterior tape tail as femur is gradually lowered to starting position.



Flex femur, allow to internally rotate and adduct onto supporting surface of table then adhere posterior tape tail towards apex of sacrum to surround gluteus maximus muscle belly.

GLUTEUS MEDIUS & MINIMUS



ORIGIN

Dorsal section, external surface of ilium between iliac crest and posterior gluteal line, the ventral section, anterior gluteal line.

Gluteal aponeurosis.

INSERTION

Oblique ridge of lateral surface of greater trochanter of femur.

NERVE L5-S1

Superior gluteal nerve.

FUNCTION

The gluteus medius and minimus muscles act to abduct the femur. They also internally rotate the femur. Their primary function is to keep the pelvis level when the opposite leg and foot are raised. When the superior fibers of gluteus maximus are unable to act as abductors of the thigh, gluteus medius and minimus are strong enough to perform this function themselves. Anterior fibers of gluteus medius assist in flexion of the femur while posterior fibers help in extension. Gluteus minimus works in abduction and internal rotation of the hip joint, and it also helps the gluteus medius in its functions.

TAPE SPECIFICATIONS

WIDTH 2 in.

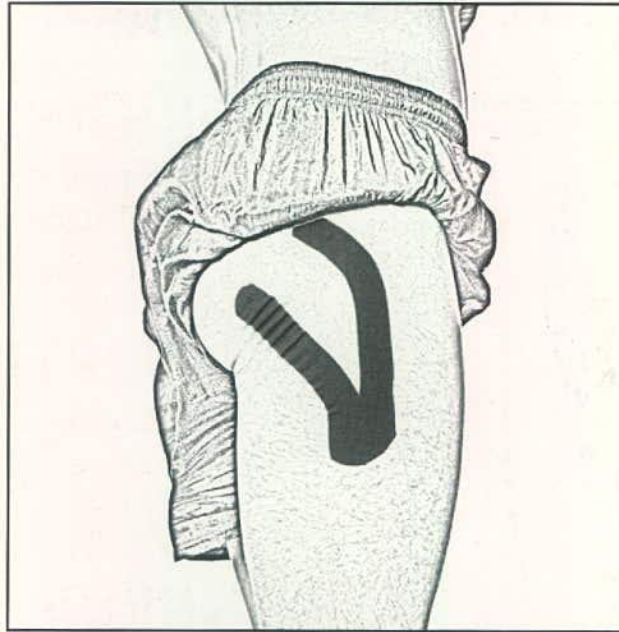
LENGTH 7 in.

Y-SHAPED TAPE

CLINICAL APPLICATION

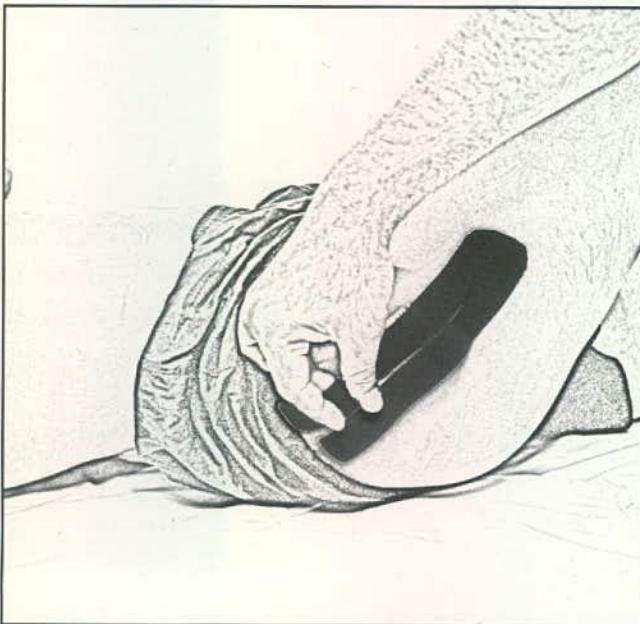
- Inflammation of the hip joint, congenital dislocation of the hip joint (Calve-Legg-Perthes syndrome), status post total hip arthroplasty (THA).

COMPLETED TAPING

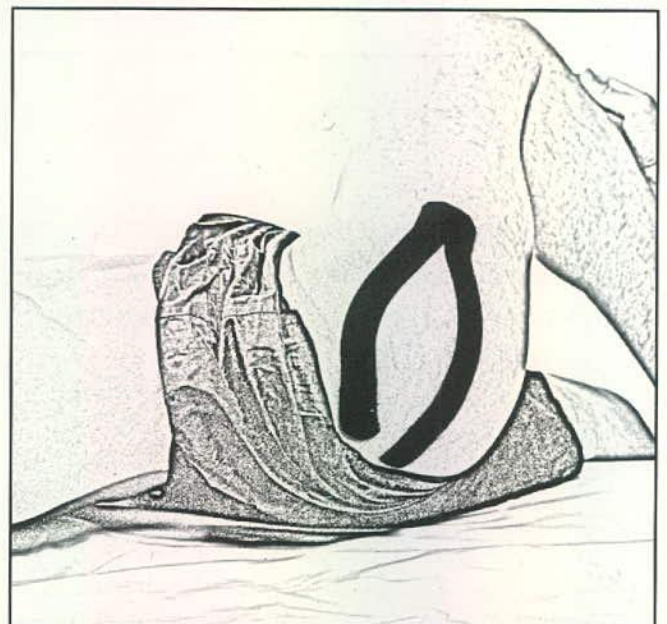


The Completed Gluteus Medius and Minimus Taping.

HOW TO ADHERE

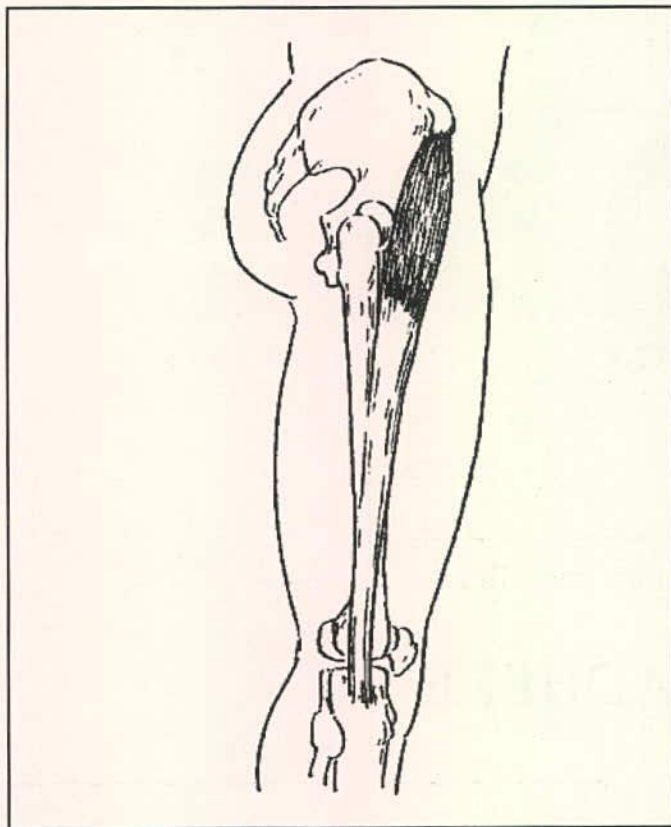


In the same manner as in gluteus maximus taping, adhere base of "Y" tape to greater trochanter. The anterior tape tail is affixed as the abducted hip is lowered to starting position.



Posterior tape tail is applied when the femur is allowed to internally rotate and adduct onto supporting surface of table.

TENSOR FASCIA LATA



ORIGIN

Anterior superior iliac spine and anterior part of iliac crest.

INSERTION

Lateral condyle of tibia by means of iliotibial tract.

NERVE L4, L5

Superior gluteal nerve.

FUNCTION

The tensor fascia lata, along with the gluteus maximus, stabilizes the hip joint and steadies the trunk on the thigh. By itself, this muscle abducts, internally rotates and flexes the thigh. Because it courses anterior to the axis of the knee, it also helps keep the knee extended.

TAPE SPECIFICATIONS

WIDTH 2 in.

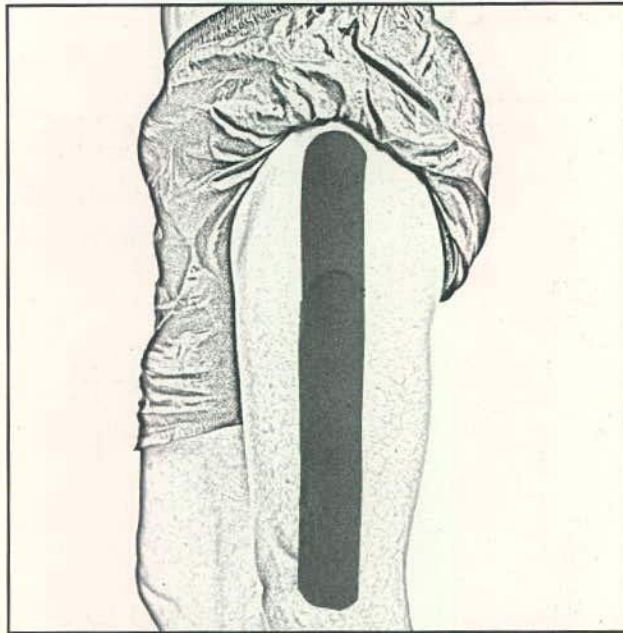
LENGTH 8 in.

I-SHAPED TAPE

CLINICAL APPLICATION

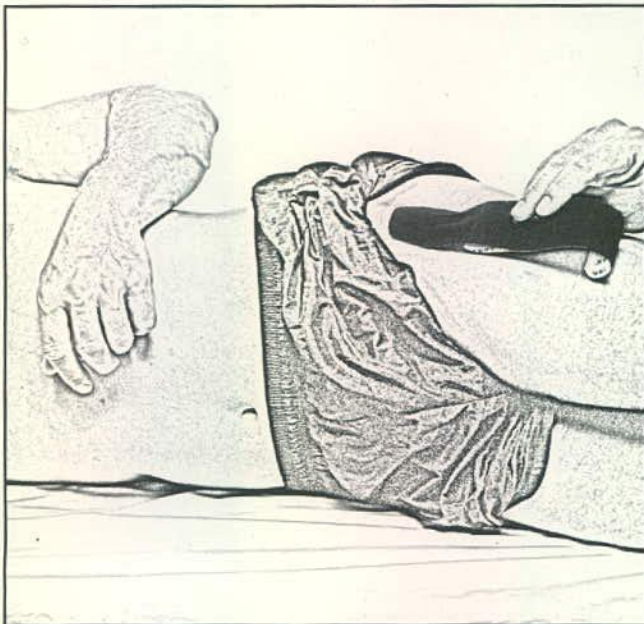
- Intervertebral disc herniation, inflammation of the hip joint, irritation of the lateral knee joint, sciatica from the upper lumbar vertebrae.

COMPLETED TAPING

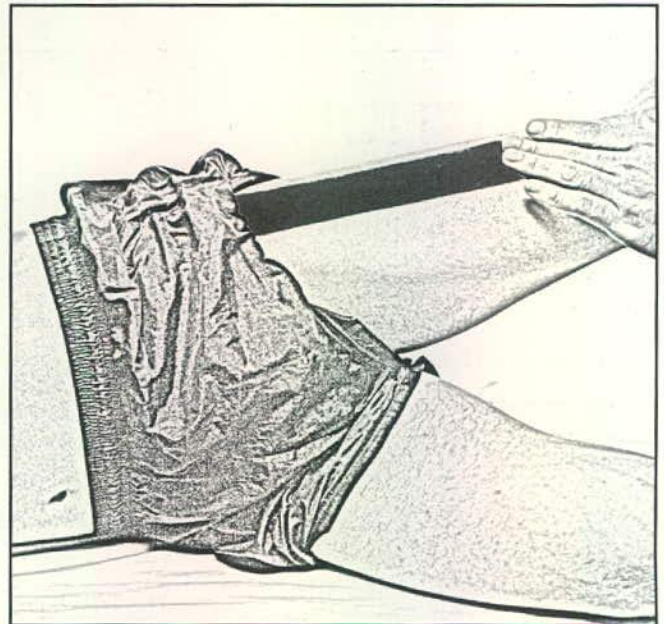


The Completed Tensor Fascia Lata Taping.

HOW TO ADHERE

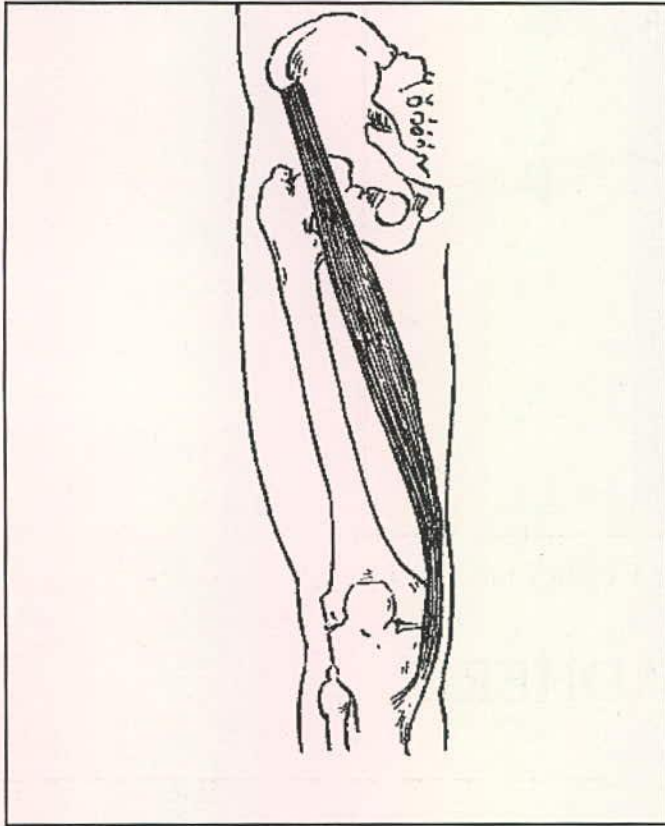


Patient in side lying with hip abducted.
Affix one end of the tape to iliac crest.



Adhere tape so that it passes over greater trochanter.
While gradually adducting leg, adhere tape at the point of maximum adduction.

SARTORIUS



ORIGIN

Anterior superior iliac spine (ASIS) and superior half of notch just inferior to it.

INSERTION

Proximal part of anterior and medial surface of tibia.

NERVE L2, L3

Femoral nerve.

FUNCTION

The sartorius flexes, abducts and externally rotates the thigh at the hip, and also helps to flex the leg at the knee joint. Although the majority of this muscle is found in the anterior compartment of the thigh, it functions to flex and internally rotate the knee joint. When sartorius is weak, it causes angling of the pelvis and knee pain, most frequently seen in the medial part of the knee joint. The name of the muscle comes from the position of sitting cross-legged on the floor, a position once used by tailors hundreds of years ago.

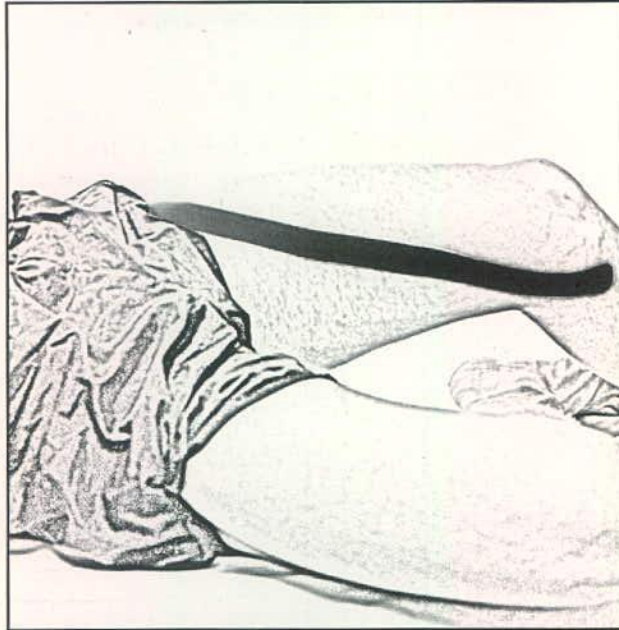TAPE SPECIFICATIONS

WIDTH 1 in.
LENGTH 18 in.
I-SHAPED TAPE

CLINICAL APPLICATION

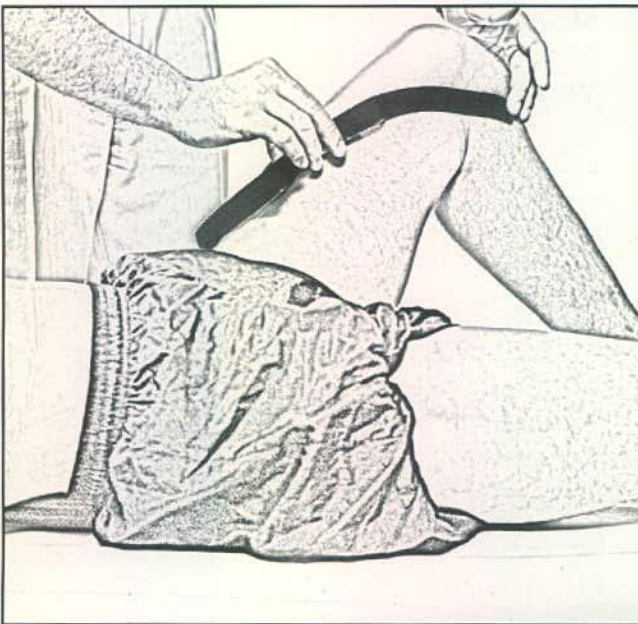- Hip joint conditions, knee conditions.

COMPLETED TAPING

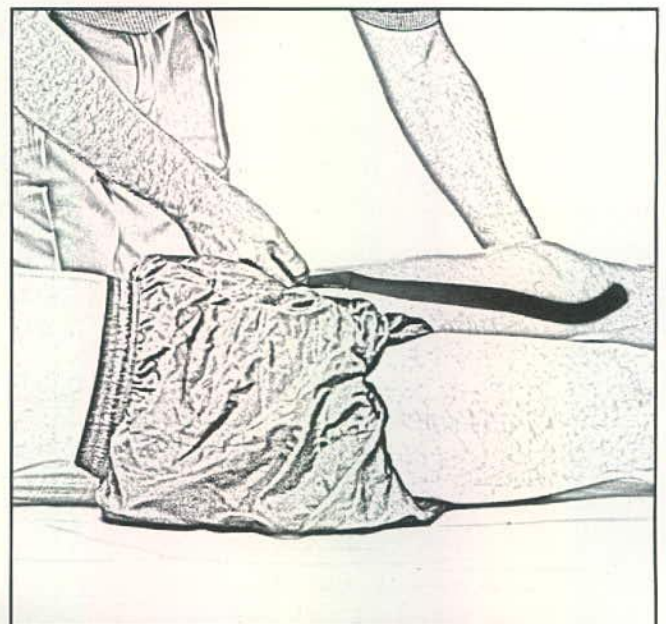


Completed taping in supine position. When walking, care should be taken that tape does not pull.

HOW TO ADHERE

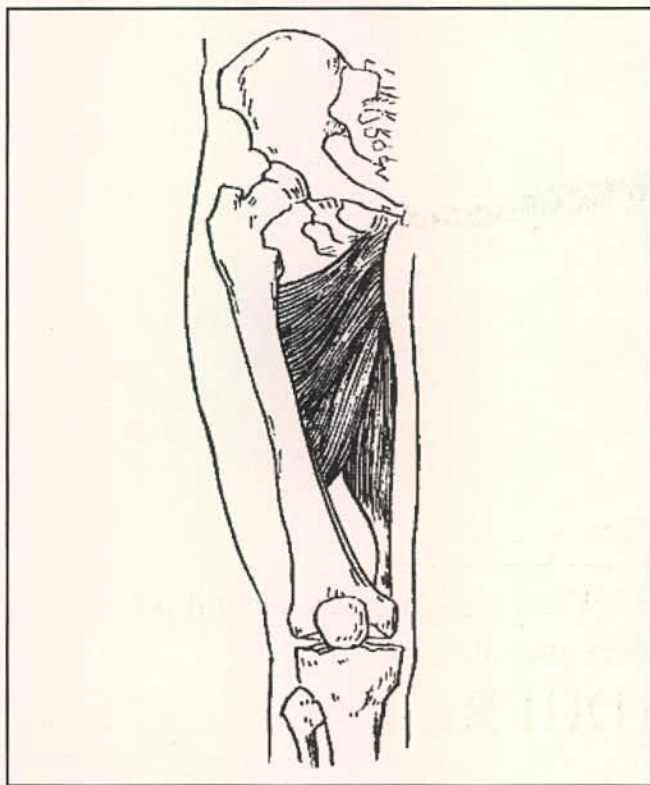


Patient in supine, propped on elbow, hip abducted and in external rotation, hip and knee in moderate flexion. Adhere tape base to region of proximal part of medial surface to tibia, medial border.



Tape is angled toward ASIS and applied as hip is brought into internal rotation, and hip and knee are gradually extended.

ADDUCTORS



FUNCTION

The adductors as a group serve to adduct the femur on the pelvis through the hip joint. The adductor magnus is divided into an adductor portion and a hamstring portion. The adductor portion adducts and flexes the thigh, while the hamstring portion adducts and extends the thigh. Adductor magnus is also a weak internal rotator of the hip joint.

The adductor longus adducts and flexes the femur, and also helps in rotation of the femur, but weakly.

The adductor brevis adducts and flexes the femur, and is a weak hip rotator.

The gracilis muscle adducts the thigh, flexes the leg at the knee, and helps rotate it medially.

The pectineus muscle adducts and flexes the thigh, and also helps with internal rotation at the hip joint.

CLINICAL APPLICATION

- Hip joint conditions, knee conditions and pelvic conditions.

ORIGIN

ADDUCTOR MAGNUS:

Inferior ramus of pubis, ramus of ischium, Ischial tuberosity.

ADDUCTOR LONGUS:

Body of pubis inferior pubic crest.

ADDUCTOR BREVIS:

Body and inferior ramus of pubis.

GRACILIS:

Body and inferior ramus of pubis.

PECTINEUS:

Superior ramus of pubis.

INSERTION

ADDUCTOR MAGNUS:

Gluteal tuberosity, linea aspera, medial supracondylar line, and adductor tubercle.

ADDUCTOR LONGUS:

Middle third of linea aspera.

ADDUCTOR BREVIS:

Pectineal line and proximal linea aspera.

GRACILIS:

Superior part of medial tibia.

PECTINEUS:

Pectineal line of femur.

NERVE

ADDUCTOR MAGNUS: L2, L3, L4;

Obturator and Tibial nerves.

ADDUCTOR LONGUS: L2, L3, L4;

Obturator nerve.

ADDUCTOR BREVIS: L2, L3, L4;

Obturator nerve.

GRACILIS: L2, L3;

Obturator nerve.

PECTINEUS: L2, L3

Obturator and femoral nerves.

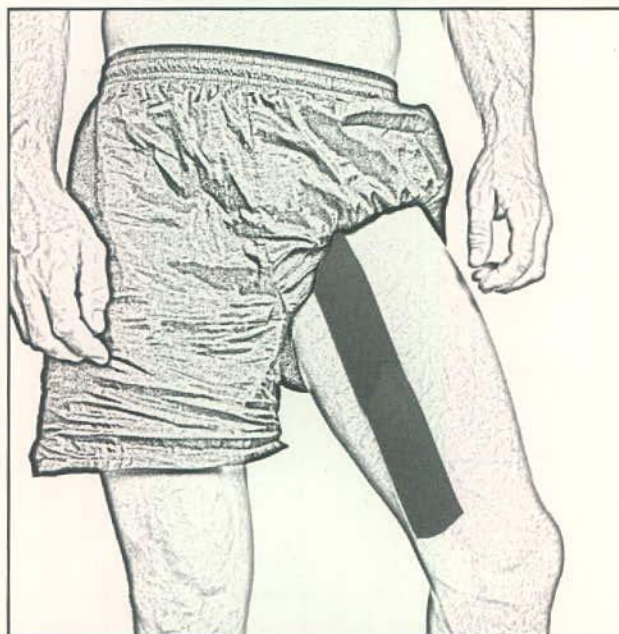TAPE SPECIFICATIONS

WIDTH 2 in.

LENGTH 8 in.

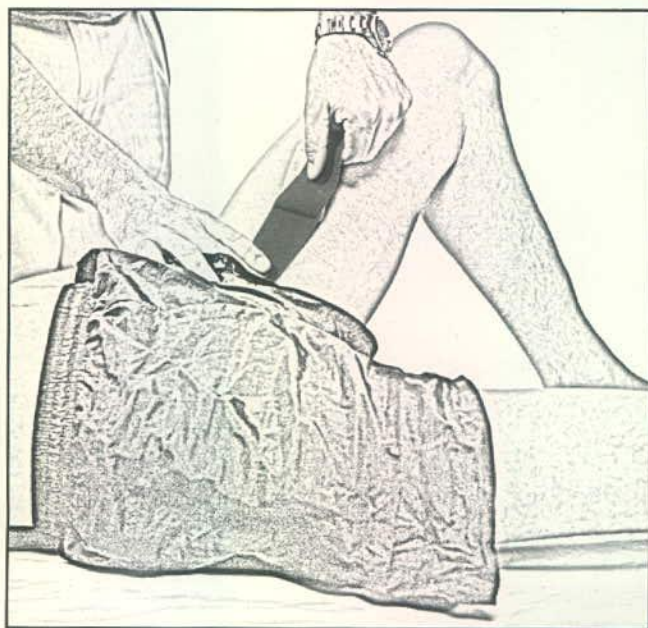I-SHAPED TAPE

COMPLETED TAPING

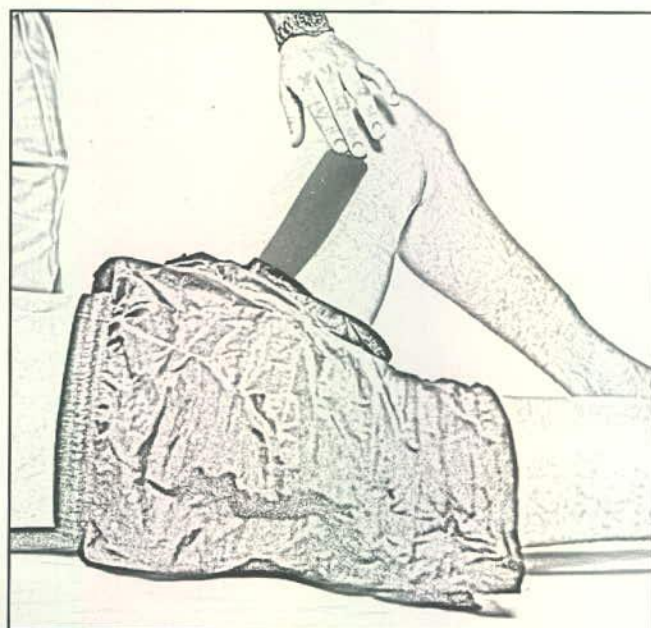

The Completed Adductors Taping.

HOW TO ADHERE

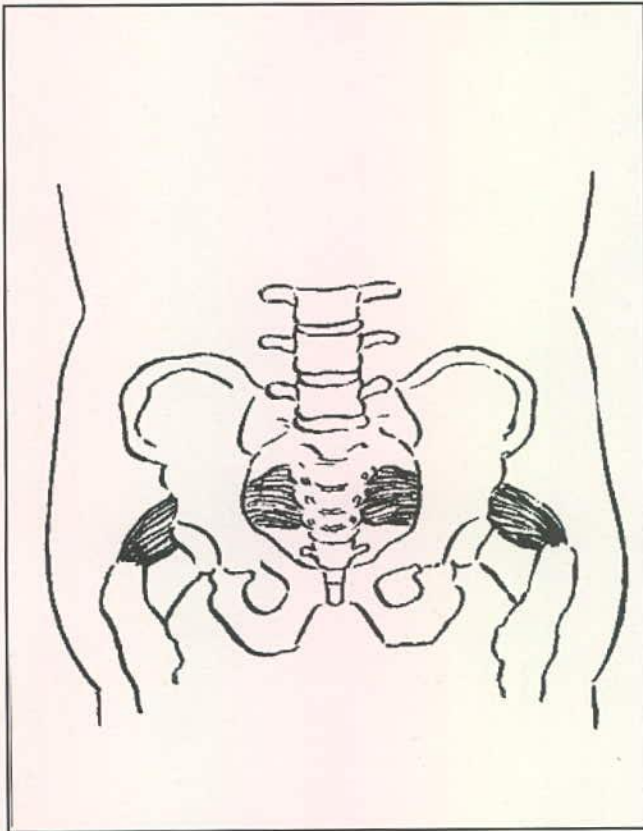


Flex knee to 90°, and adduct thigh.
Adhere one end of tape just distal to groin.



While abducting leg, adhere tape when hip is fully abducted.

PIRIFORMIS



ORIGIN

Anterior surface of sacrum within the pelvis, and sacrotuberous ligament.

INSERTION

Superior border of greater trochanter of femur.

NERVE S1-S2

Nerve to piriformis

FUNCTION

The piriformis works in external rotation and extension of the hip. This muscle acts with the obturator internus, superior and inferior gemellae, and quadratus femoris to steady the head of the femur in the acetabulum.

When the piriformis becomes weak, it sometimes has adverse effects of the sciatic nerve due to the fact that in 15-20% of people, sciatic nerve components pass through the muscle as they make their way into the buttock. Paresthesias or pain may result from this impingement.

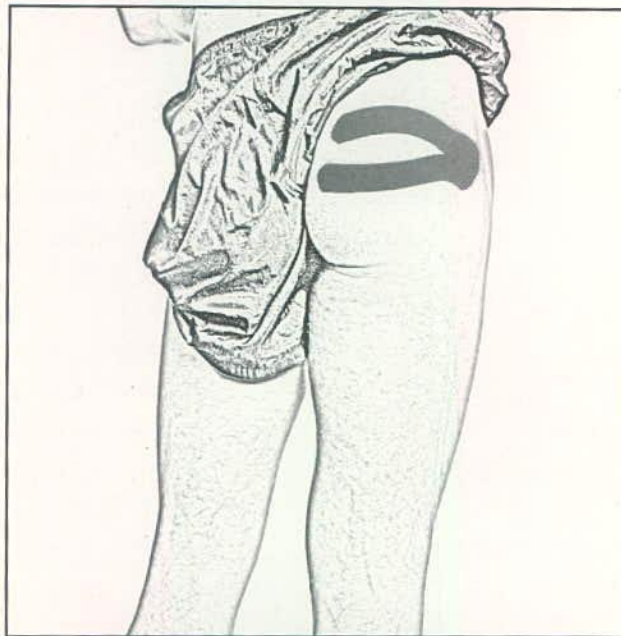
TAPE SPECIFICATIONS

WIDTH 2 in.
LENGTH 6 in.
Y-SHAPED TAPE

CLINICAL APPLICATION

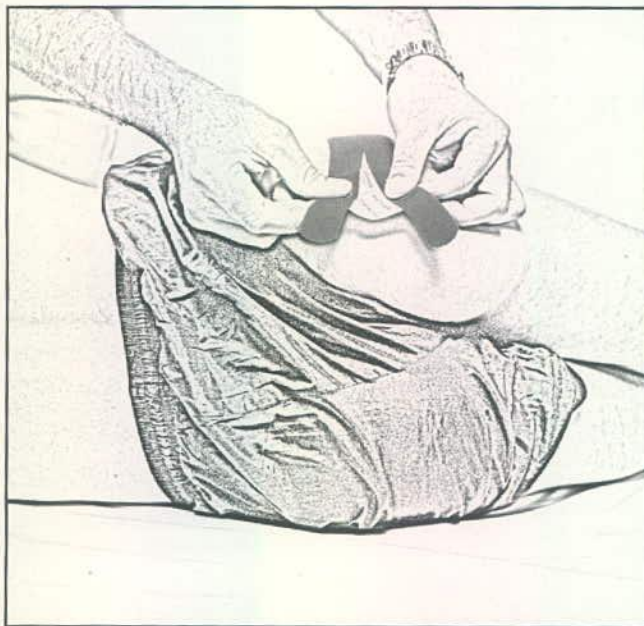
- Piriformis syndrome, hip joint conditions, sciatica.

COMPLETED TAPING

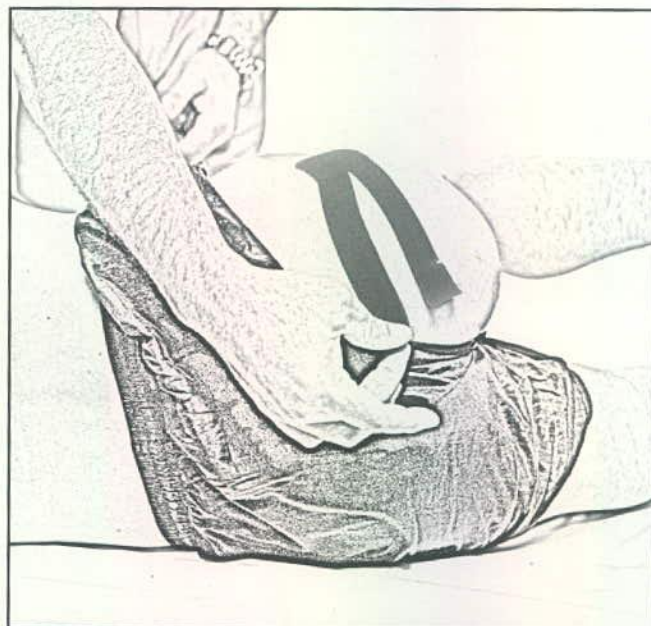


The Completed Piriformis Taping.

HOW TO ADHERE

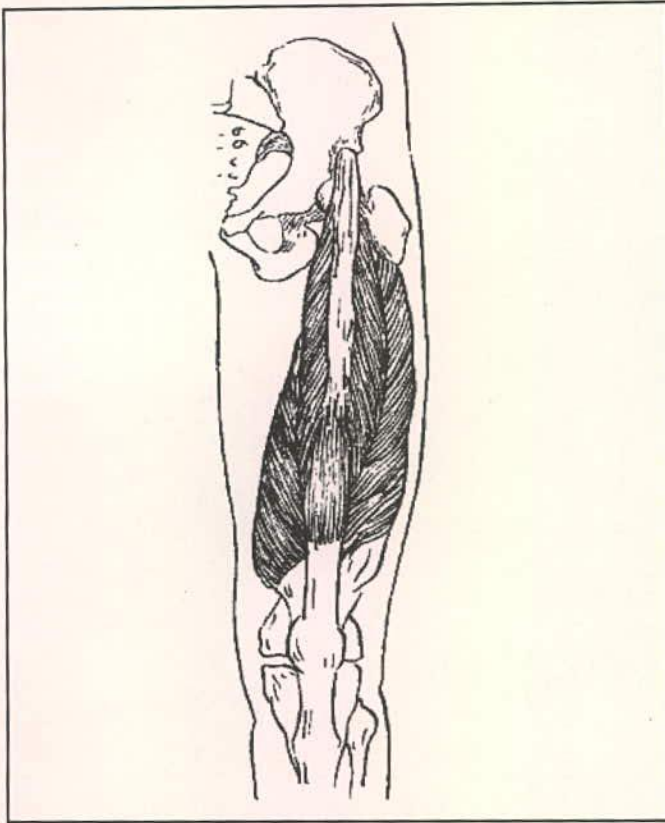


The patient lies on side, knee flexed to 120°, and hip abducted. First adhere the base at greater trochanter. Next adhere one end of tape towards sacrum.



With remaining end of tape, point toward lower buttocks and slightly abducting hip. While flexing hip towards chest, affix tape.

QUADRICEPS FEMORIS



ORIGIN

RECTUS FEMORIS:

Anterior inferior iliac spine, groove above acetabulum.

VASTUS INTERMEDIUS:

Upper 2/3rd of anterior surface of shaft of femur.

VASTUS MEDIALIS:

Distal half of intertrochanteric line, medial hip of linea aspera and proximal part of medial supracondylar line.

VASTUS LATERALIS:

Upper half of intertrochanteric line, anterior and inferior rim of greater trochanter, lateral lip of gluteal tuberosity, proximal half of lateral lip of linea aspera.

INSERTION

Base of patella.

NERVE L2-L4

Femoral nerve.

FUNCTION

The quadriceps femoris, the strong extensor of the knee, is made up of four muscles: rectus femoris, vastus lateralis, vastus intermedius and vastus medialis. There appears to not be a reason to differentiate a specialized subdivision called vastus medialis obliquus.

Within this group only rectus femoris traverses two joints. This means that this muscle is used in the movement of two joints. This subdivision of the quadriceps acts to help iliopsoas to flex the thigh.

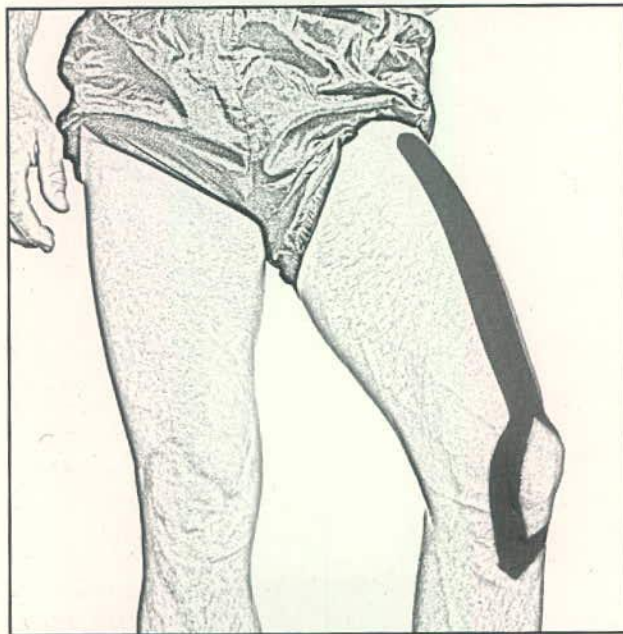TAPE SPECIFICATIONS

WIDTH 2 in.
LENGTH 10-12 in.
I-SHAPED TAPE

CLINICAL APPLICATION

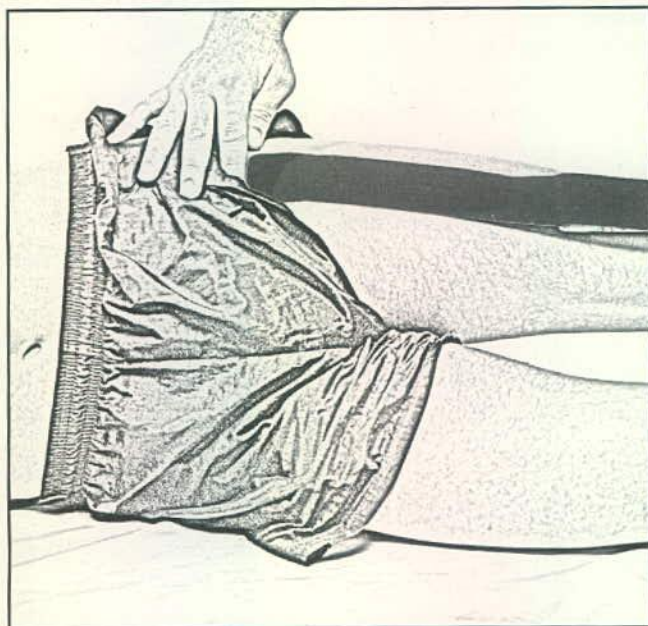
- Visceroptosis, mid-back ache.

COMPLETED TAPING

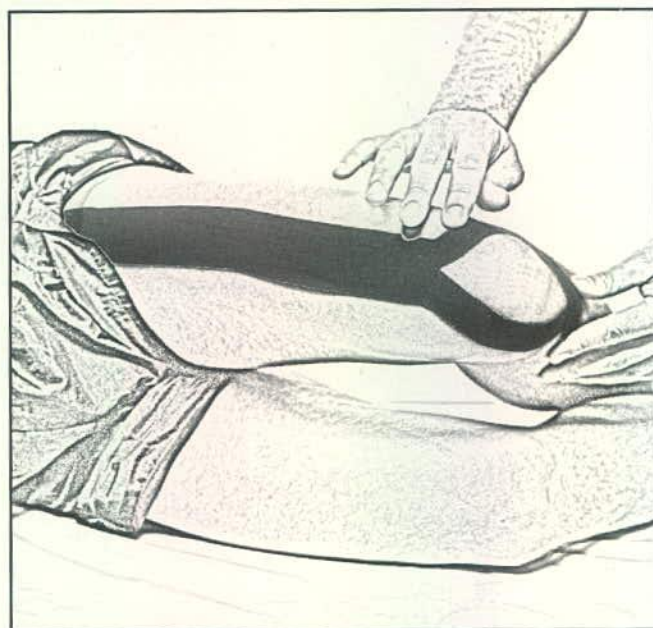


The Completed Quadriceps Femoris Taping.

HOW TO ADHERE

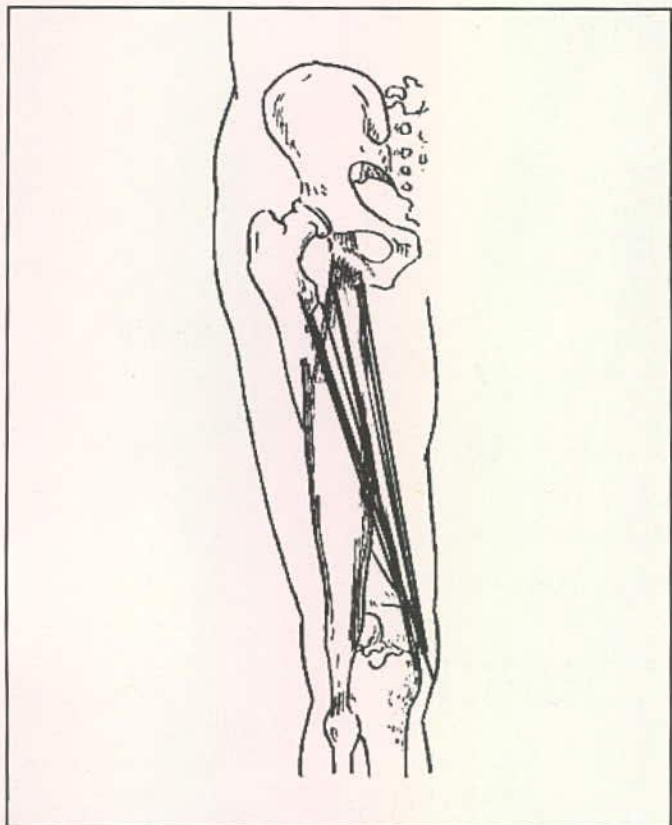


Supine with knee extended.
Adhere base of tape to the belly of quadriceps femoris and line tape up towards patella.
Separate two tape tails of "Y".



Flex knee and adhere tape tails around patella to finish at tibial tuberosity.

HAMSTRINGS



ORIGIN

SEMIMEMBRANOSUS:

Ischial tuberosity.

SEMITENDINOSUS:

Ischial tuberosity.

BICEPS FEMORIS:

LONG HEAD: Ischial tuberosity.

SHORT HEAD: Linea aspera.

INSERTION

SEMIMEMBRANOSUS:

Posterior part of medial tibial condyle.

SEMITENDINOSUS:

Anteromedial part of proximal tibia.

BICEPS FEMORIS:

Fibular head.

NERVE L5, S1, S2

Tibial nerve (Semimembranosus, Semitendinosus, Long head of Biceps femoris).

Common peroneal nerve (Short head of Biceps femoris).

FUNCTION

The semimembranosus, semitendinosus and long head of the biceps femoris act to extend the thigh and they also are strong flexors of the knee joint. The semimembranosus and semitendinosus muscles can internally rotate the leg. The short head of the biceps femoris flexes the leg and externally rotates it at the knee joint. When the thigh and leg are flexed, these muscles can also extend the trunk through their action on the pelvis. In short, the hamstring muscles are able to stabilize the lumbar region, extend the thigh from the flexed position, and help in internal and external rotation of the leg at the knee joint.

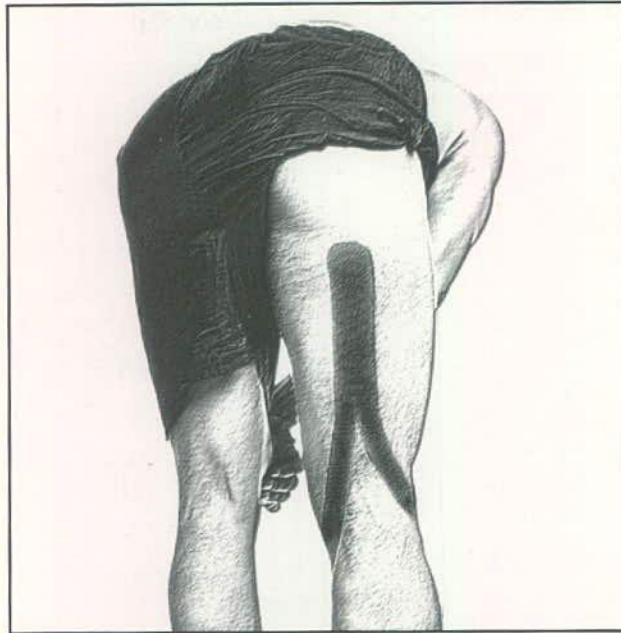
TAPE SPECIFICATIONS

WIDTH	2 in.
LENGTH	10-18 in.
Y-SHAPED TAPE	

CLINICAL APPLICATION

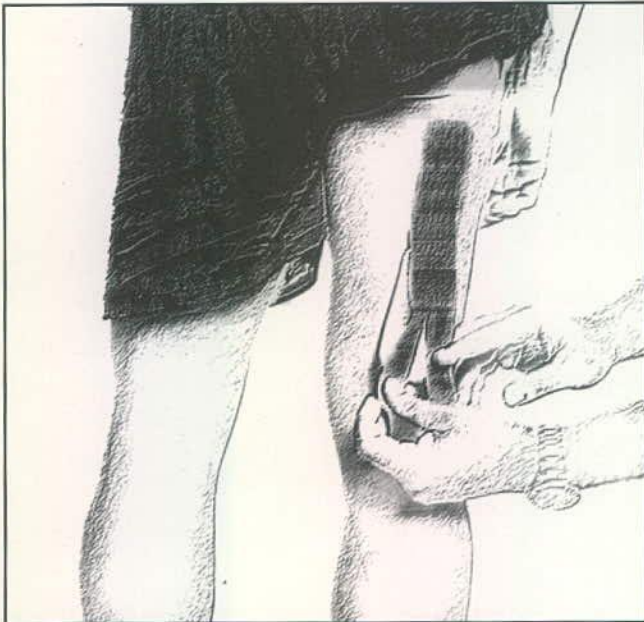- Internal derangement of the knee, osteoarthritis of the knee, damage to the tibial collateral ligament, damage to the semi-lunar cartilage.

COMPLETED TAPING

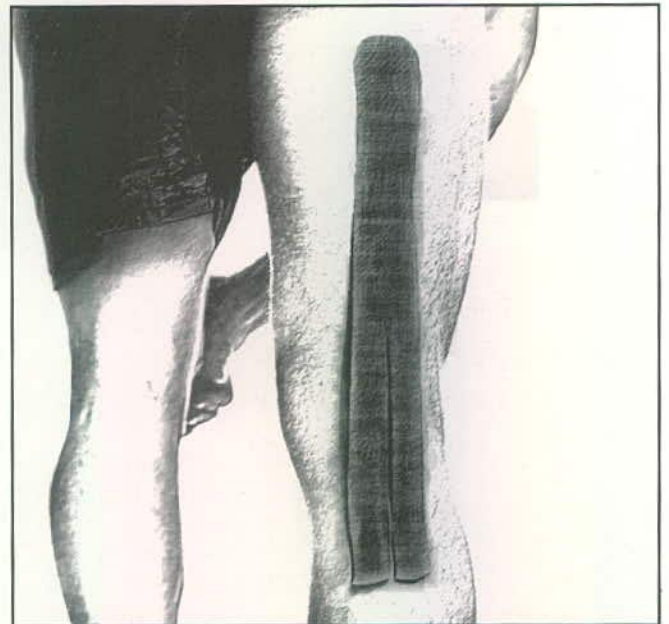

The Completed Hamstrings Taping.

HOW TO ADHERE

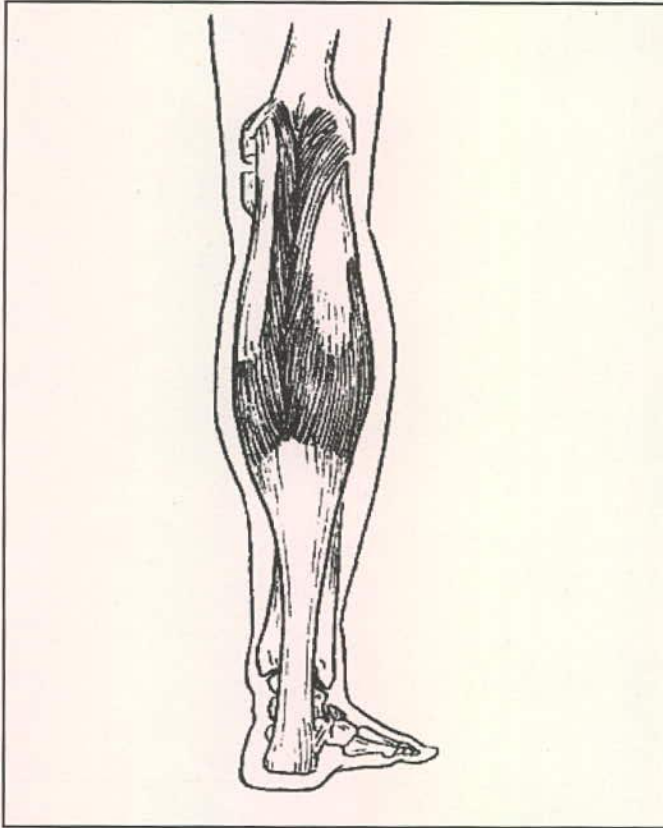


With patient prone, knee moderately flexed and hip somewhat extended. Adhere tape base of proximal thigh in line with ischial tuberosity. As knee is gradually extended, apply tape tail to one side of knee.



Return knee to flexed position. As knee is gradually extended, adhere 2nd tape tail to other side of knee.

SOLEUS and GASTROCNEMIUS



ORIGIN

SOLEUS:

Posterior surface of head of fibula; proximal 1/3 of posterior surface of fibula; soleal line and medial border of tibia.

GASTROCNEMIUS:

LATERAL HEAD:

Lateral condyle and posterior part of medial condyle.

MEDIAL HEAD:

Proximal and posterior part of medial condyle.

INSERTION

Posterior surface of calcaneus by means of Achille's tendon (tendo calcaneus).

NERVE S1, S2

Tibial nerve.

FUNCTION

The superficial plantar flexors of the foot are also termed the triceps surae. This group consists of soleus, gastrocnemius and plantaris muscles. Since they enter the foot on the medial side, they also are very strong invertors of the ankle and foot.

TAPE SPECIFICATIONS

WIDTH 2 in.

LENGTH 12 in. for Soleus.

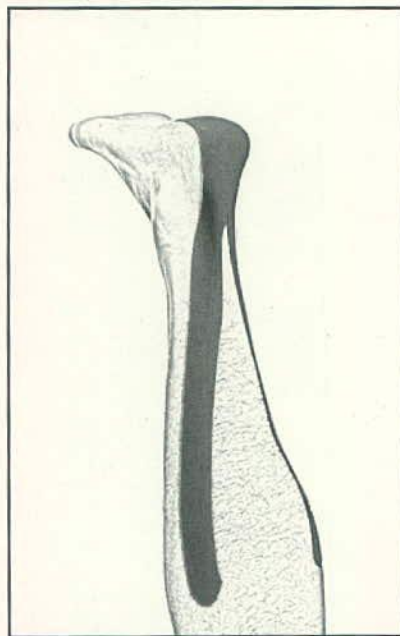
15-20 in. for Gastrocnemius.

Y-SHAPED TAPE

CLINICAL APPLICATION

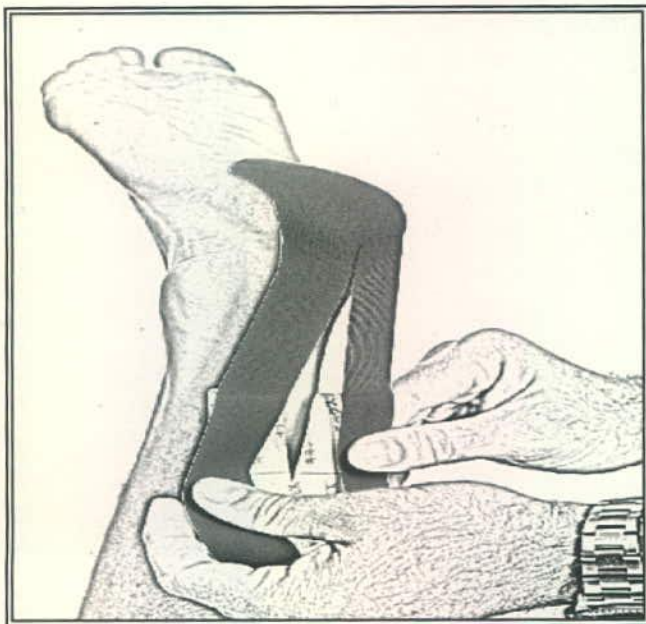
- Inflammation of the Achille's tendon, ankle conditions, pain on the plantar surface of the heel.

COMPLETED TAPING

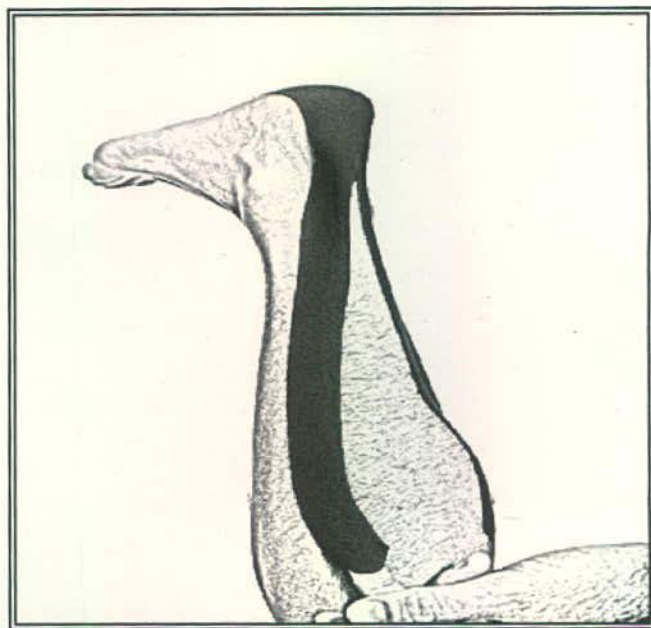


The Completed Soles & Gastrocnemius Taping.

HOW TO ADHERE

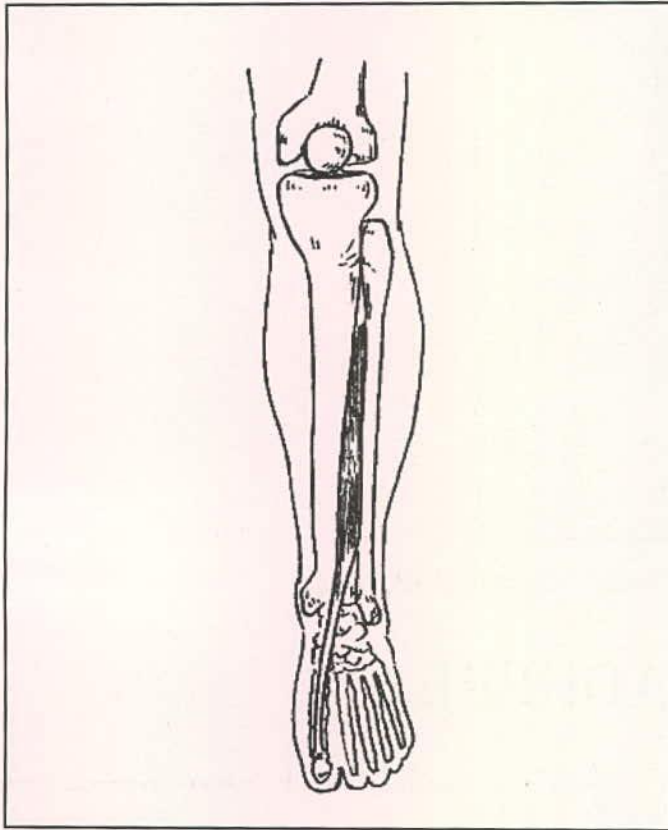


Patient in prone with knee flexed, or in hands-and-knees (quadruped) position to allow plantar surface of foot to be seen easily. First, adhere base of tape to plantar surface of heel. Adhere tape over Achille's tendon as ankle is dorsiflexed.



While maintaining ankle dorsiflexion, apply tape tails to posterior surface of leg to surround soleus and gastrocnemius muscle complex to finish.

EXTENSOR HALLUCIS LONGUS



ORIGIN

Middle part of anterior surface of fibula and interosseous membrane.

INSERTION

Dorsal aspect distal phalanx of great toe.

NERVE L5, S1

Deep peroneal (fibular) nerve.

FUNCTION

Extends both joints of the great toe; assists anterior tibialis muscle in ankle dorsiflexion and inversion.

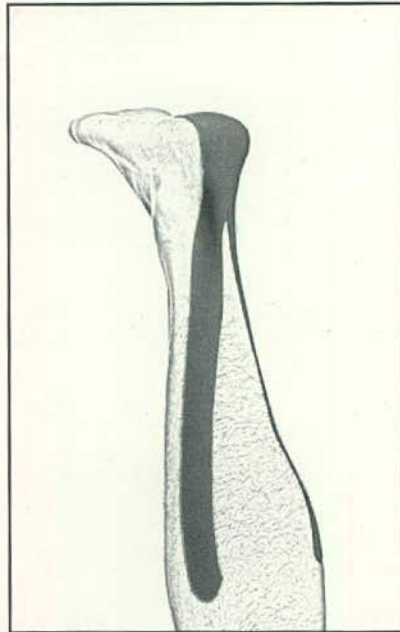
TAPE SPECIFICATIONS

WIDTH 1 in.
LENGTH 14 in.
Y-SHAPED TAPE

CLINICAL APPLICATION

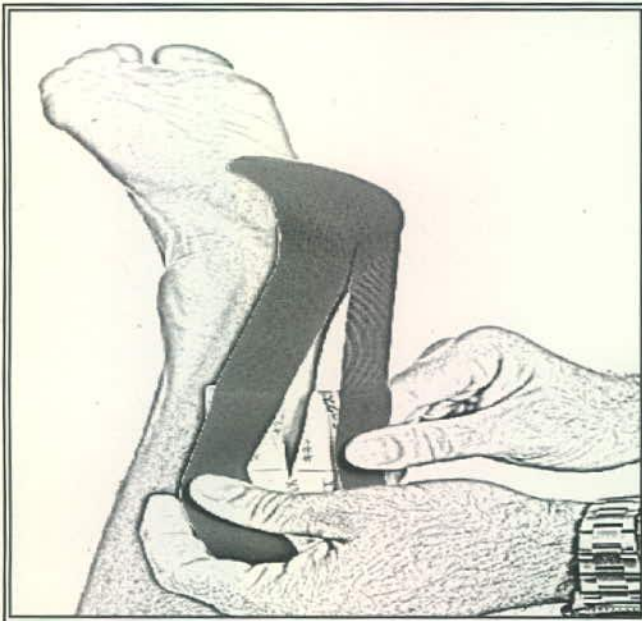
- Sprained ankle, osteoarthritis of the ankle.

COMPLETED TAPING

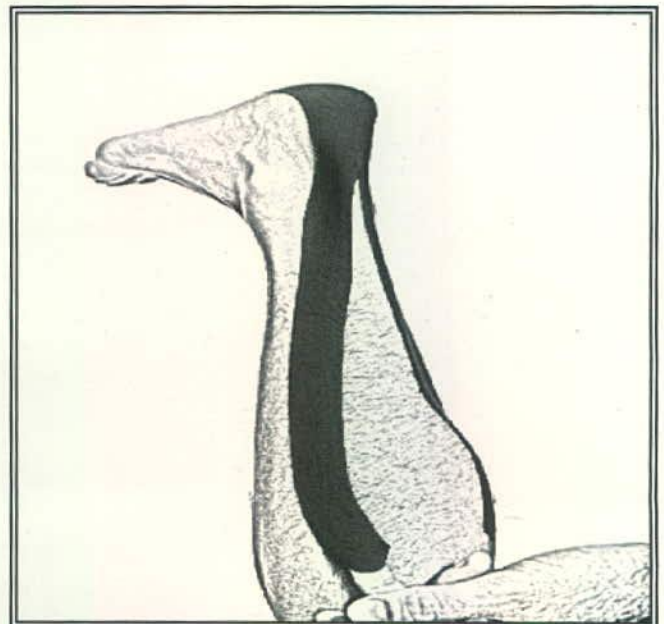


The Completed Soles & Gastrocnemius Taping.

HOW TO ADHERE

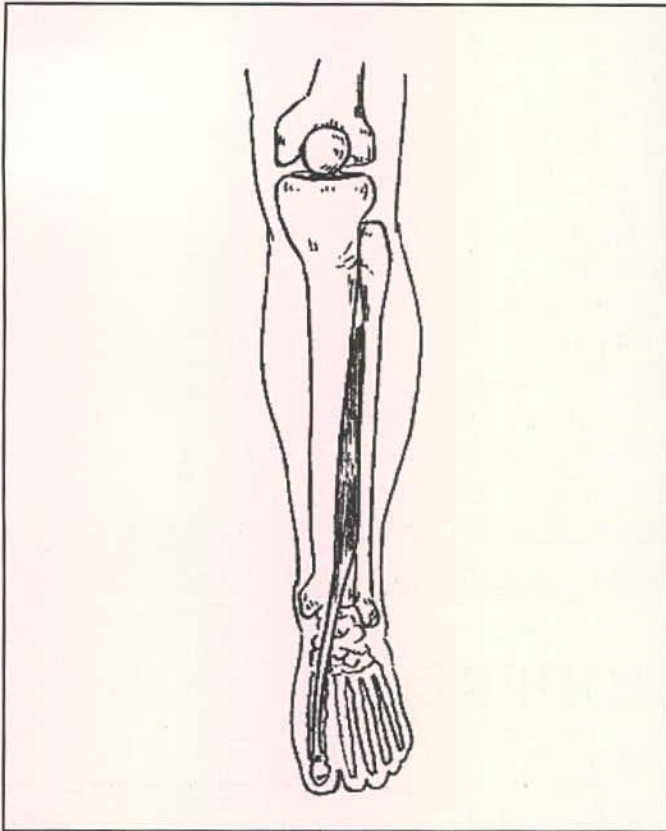


Patient in prone with knee flexed, or in hands-and-knees (quadruped) position to allow plantar surface of foot to be seen easily. First, adhere base of tape to plantar surface of heel. Adhere tape over Achille's tendon as ankle is dorsiflexed.



While maintaining ankle dorsiflexion, apply tape tails to posterior surface of leg to surround soleus and gastrocnemius muscle complex to finish.

EXTENSOR HALLUCIS LONGUS



ORIGIN

Middle part of anterior surface of fibula and interosseous membrane.

INSERTION

Dorsal aspect distal phalanx of great toe.

NERVE L5, S1

Deep peroneal (fibular) nerve.

FUNCTION

Extends both joints of the great toe; assists anterior tibialis muscle in ankle dorsiflexion and inversion.

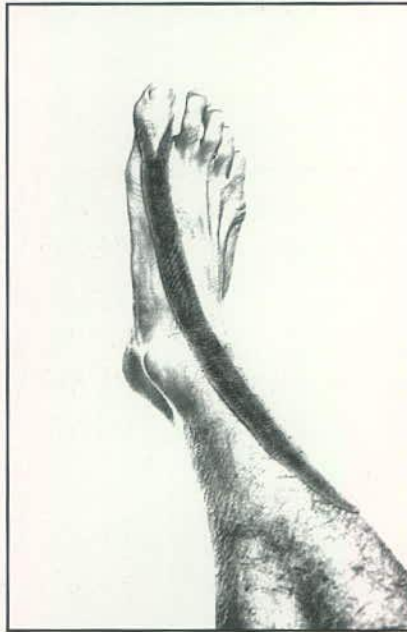
TAPE SPECIFICATIONS

WIDTH 1 in.
LENGTH 14 in.
Y-SHAPED TAPE

CLINICAL APPLICATION

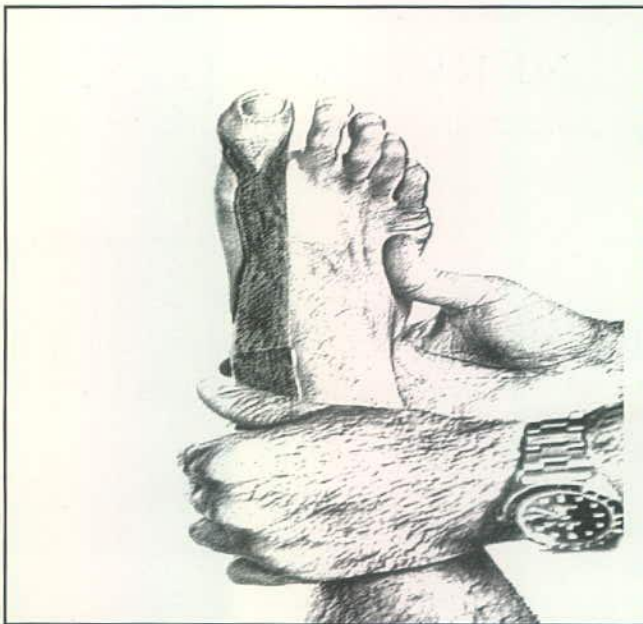
- Sprained ankle, osteoarthritis of the ankle.

COMPLETED TAPING



The Completed Extensor Halluces Longus Taping.

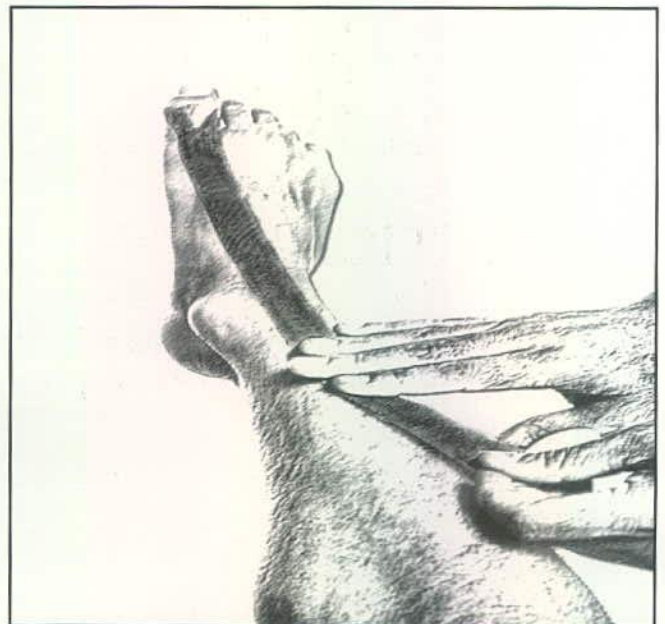
HOW TO ADHERE



Dorsiflex ankle to maximum and plantar flex great toe.

Start by fixing "V" section of tape to great toe.

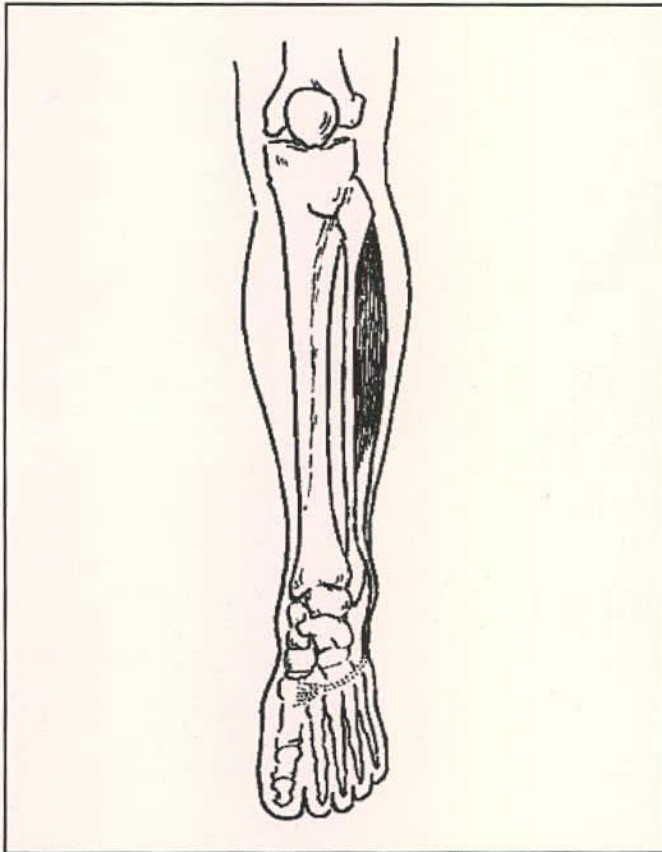
Planter flex ankle to maximum and affix tape.



Return ankle to dorsi flexed position, line tape up along tibialis anterior.

With ankle plantar flexed to maximum, adhere tape.

PERONEUS LONGUS & BREVIS



ORIGIN

PERONEUS LONGUS:

Head and superior 1/3 of lateral surface of fibula.

PERONEUS BREVIS:

Inferior 2/3 of lateral surface of fibula.

INSERTION

PERONEUS LONGUS:

Plantar surface of base of 1st metatarsal and medial cuneiform bones.

PERONEUS BREVIS:

Lateral side of base of 5th metatarsal bone.

NERVE L5, S1, S2

Superficial peroneal (fibular) nerve.

FUNCTION

The peroneal muscles evert the foot. Because they enter the foot posterior to the joint axis, they also plantar flex the ankle and foot. These muscles act to resist inversion ankle sprain.

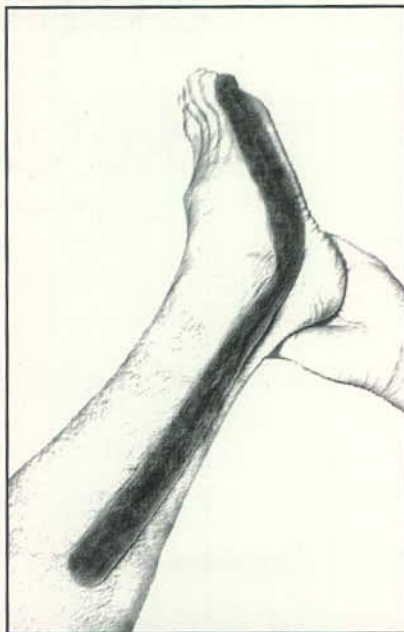TAPE SPECIFICATIONS

WIDTH 1 in.
LENGTH 14 in.
I-SHAPED TAPE

CLINICAL APPLICATION

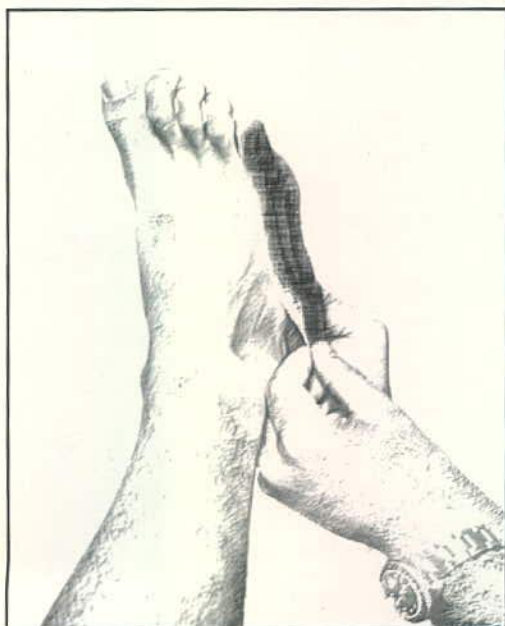
- Inflammation of peroneal nerve, ankle sprain.

COMPLETED TAPING

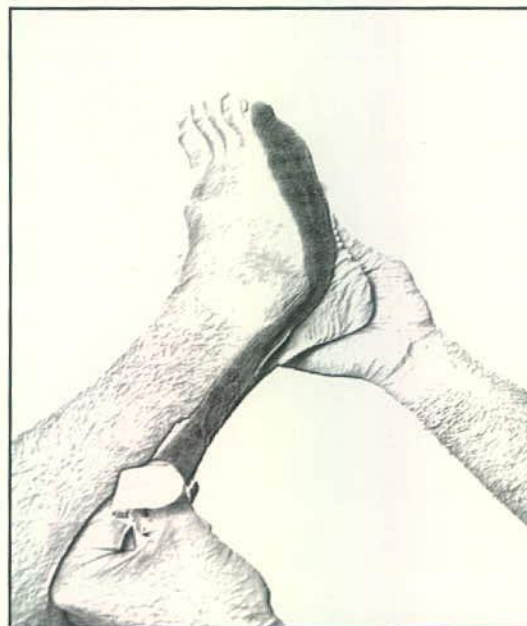

The Completed Foot Eversion & Peroneus Longus Taping.

HOW TO ADHERE

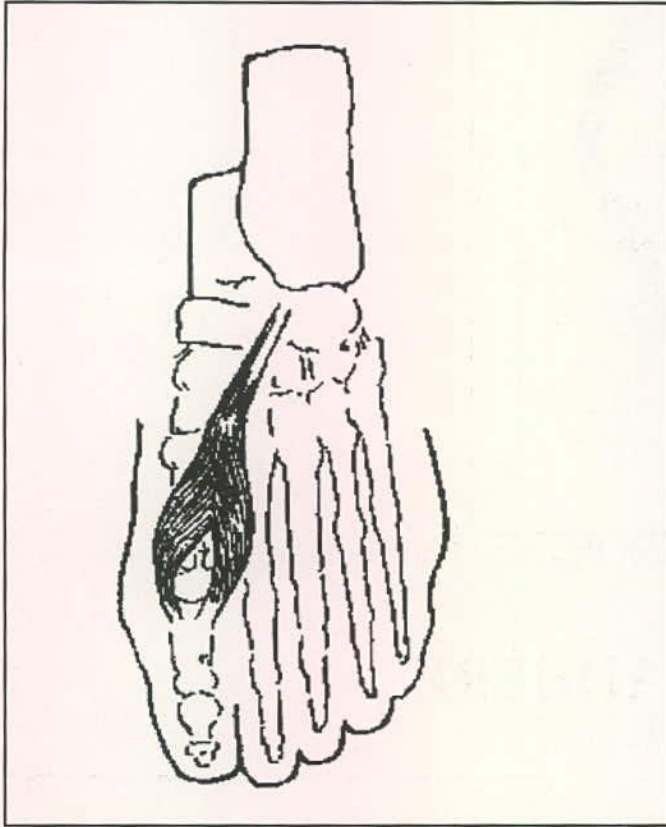


Supine, knee slightly flexed to about 30° with ankle everted. Adhere base of tape to base of 5th metatarsal for peroneus brevis, or along medial part of instep just in front of calcaneus for peroneus longus. Apply tape and hold tape down on lateral malleolus.



Apply tape along lateral leg following course of peroneal muscles, while the ankle and foot are placed in inversion and dorsiflexion, to finish.

FLEXOR HALLUCIS BREVIS



ORIGIN

Plantar surfaces of cuboid and lateral cuneiform bones.

INSERTION

Medial and lateral parts of base of proximal phalanx of great toe.

NERVE S2, S3

Medial plantar nerve.

FUNCTION

Flexes proximal phalanx of 1st toe. This muscle is extremely necessary in maintaining balance and in support of the longitudinal arch.

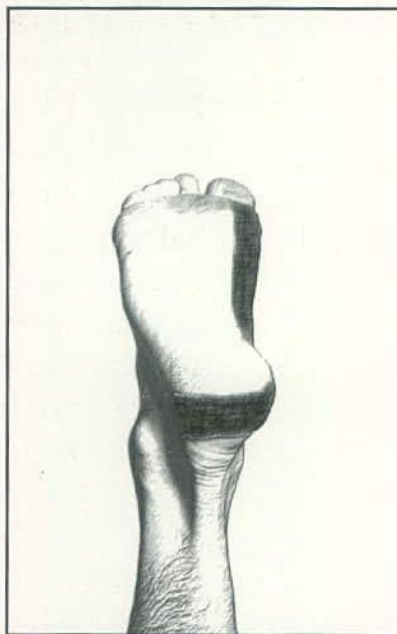
TAPE SPECIFICATIONS

WIDTH 1 in.
LENGTH 6-7 in.
Y-SHAPED TAPE

CLINICAL APPLICATION

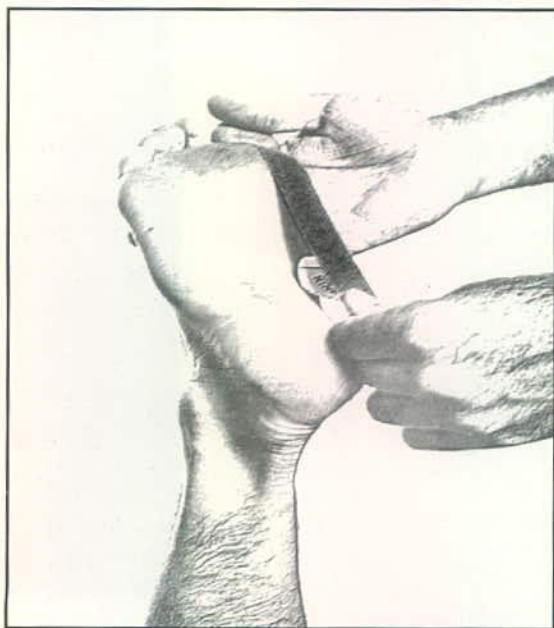
- Pain in the base of the heel, longitudinal arch, dropped arch (flat foot); turf toe in athletes.

COMPLETED TAPING



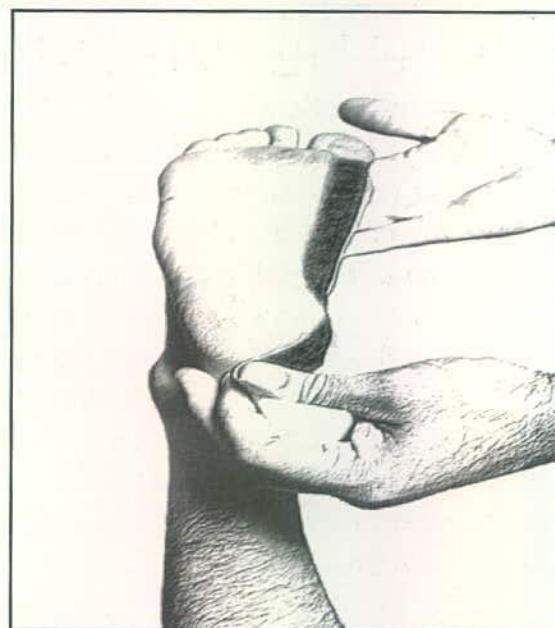
The Completed Flexor Halluces Brevis Taping.

HOW TO ADHERE



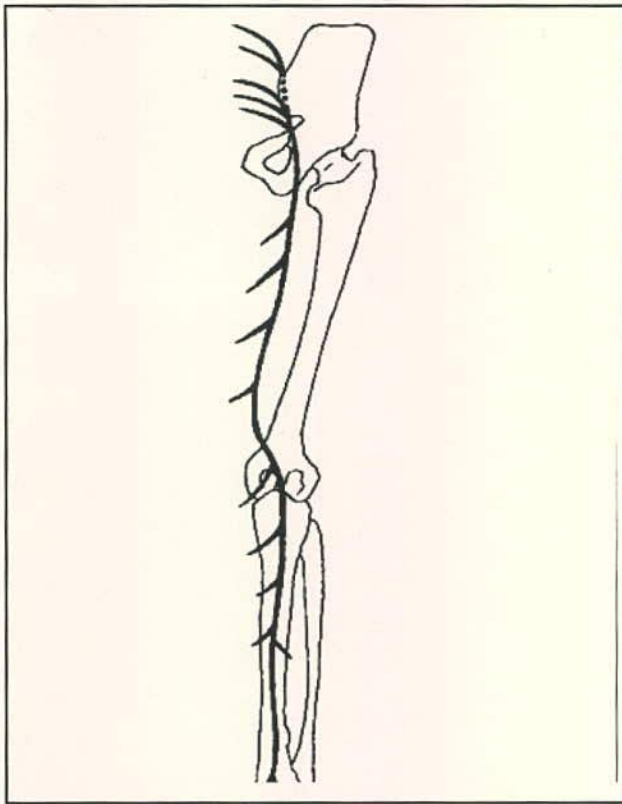
The patient is prone, knee flexed and sole of foot facing up.

Firstly wrap the "V" section around great toe.



Next, hyperextend great toe from metatarsophalangeal (MTP) joint. Affix tape to posterior aspect of heel to finish.

SCIATIC NERVE TAPE



FACTORS IN SCIATICA

If the intervertebral disc of L4-5 exerts pressure on the nerve root of L5, paresthesia and pain can result in the back, front, and lateral aspect of the thigh, front and back of the leg, and dorsum and plantar surface of the foot, including the great toe. There are also instances where the feeling over the lateral malleolus is disturbed with weakness found in the dorsiflexors of the ankle and extensors of the great toe.

Next, if the intervertebral disc of L5-S1 exerts pressure on the nerve root of S1, then paresthesia and pain can result. These are noted in the back of the thigh, calf and along the Achilles's tendon into the heel and lateral borders of the 4th and 5th toes. There may be associated weakness of the plantar flexors of the ankle, both superficial and deep, and toe flexors as well.

SCIATIC NERVE TAPE

LUMBOSACRAL PLEXUS FORMATION

Just as there is a brachial plexus that innervates the upper extremity, there are also lumbar and sacral plexes that govern the motor and sensory parts of the lower extremity. The lumbar plexus is formed from spinal roots of L1-L3 and part of L4. This plexus innervated the anterior and medial parts of the thigh for both motor and sensory activity. Thus, both the femoral and obturator nerves come from this part of the nervous system. The lumbosacral plexus comes from part of L4 plus L5, S1, S2, S3 and S4. It is from this plexus that the sciatic nerve is formed.

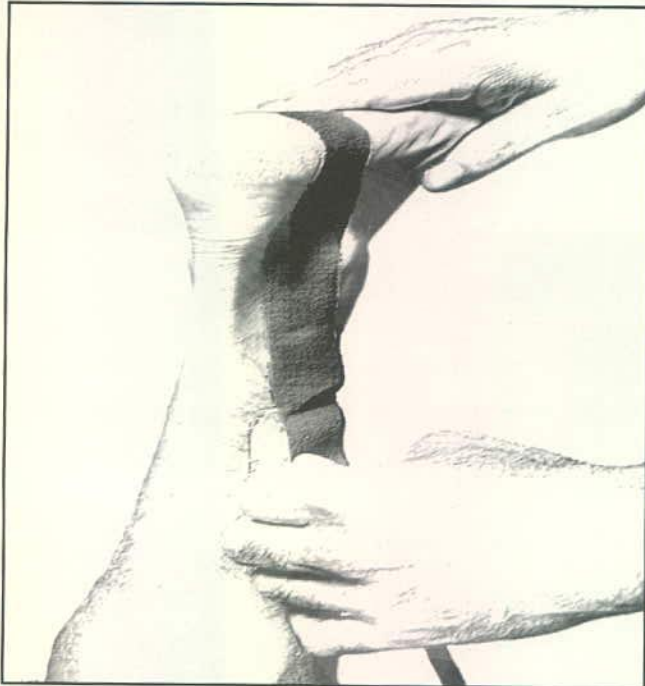The sciatic nerve originates from a part of L4, all of L5, parts of S1-S3. The L4 and L5 branch forms the superior gluteal nerve, while the S1 and S2 branch form the posterior and lateral cutaneous nerves which give sensory innervation to the posterior and lateral parts of the thigh. The sciatic nerve has two components which may exit the pelvis separately as the tibial nerve and the common peroneal (common fibular) nerve. Usually the sciatic nerve exits the pelvis just inferior to the piriformis muscle, about 70% of the time. In another 15%, the tibial nerve exits inferior to the piriformis and the common peroneal (fibular) nerve exits through the piriformis. In about 10% the tibial nerve exits inferior and the common peroneal nerve exits superior to the muscle and approximately 5% of the time, both the tibial and the personal nerves exit by piercing the belly of the piriformis muscle. These alterations from normal may be the cause of peripheral nerve impingement syndromes of the lower extremity.

The tibial nerve innervates most of the posterior thigh, and all of leg and plantar structures of the foot. The common peroneal (common fibular) nerve innervates the short head of the biceps femoris. The nerve curves around the fibular neck then splits to enter the lateral and anterior compart-

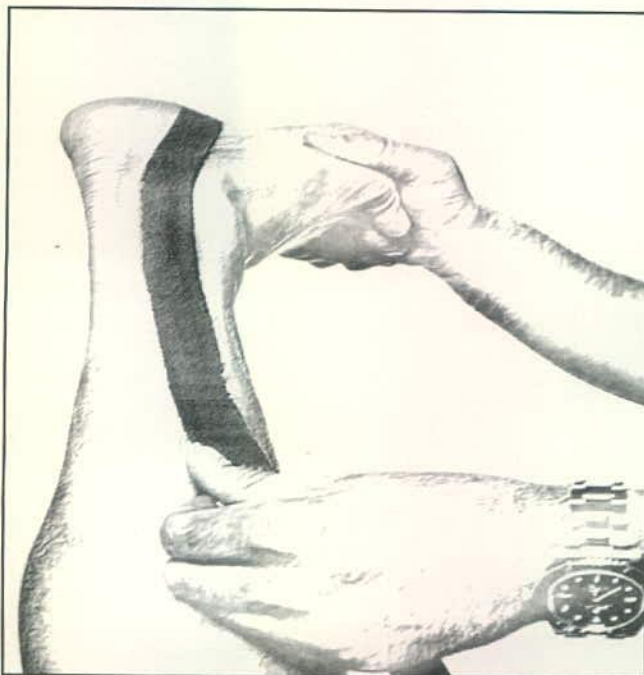
ments of the leg. In the leg, the superficial peroneal nerve innervates the peroneal muscles of the tibial compartment, and the deep peroneal nerve innervates, the anterior tibialis, extensor digitorum longus and extensor hallucis longus in the anterior compartment. The superficial peroneal nerve is sensory to most of the dorsum of the foot while the deep peroneal nerve innervates the extensor digitorum brevis muscle and then is sensory to the dorsal web space between the first two toes. Pressure applied in the leg to either the tibial or common peroneal nerves can result in paresthesias or pain in the foot.

TAPE SPECIFICATIONS

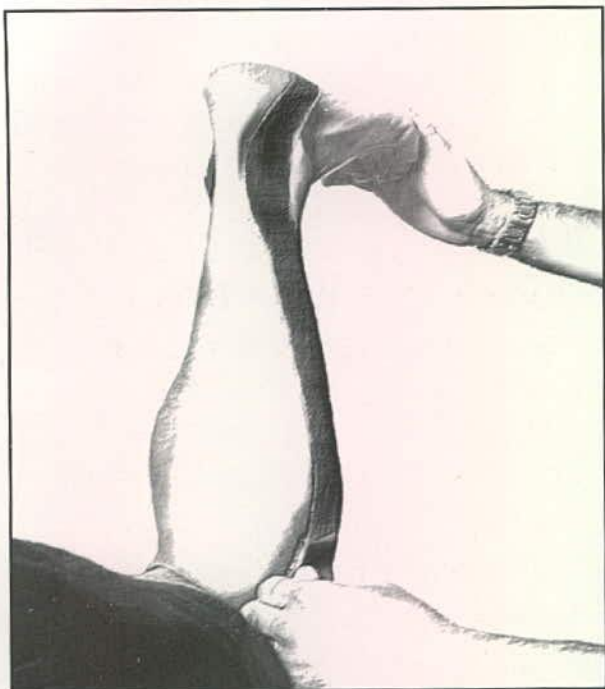
WIDTH	1.5 in.	LENGTH	36 in.	Y-SHAPED TAPE
-------	---------	--------	--------	---------------



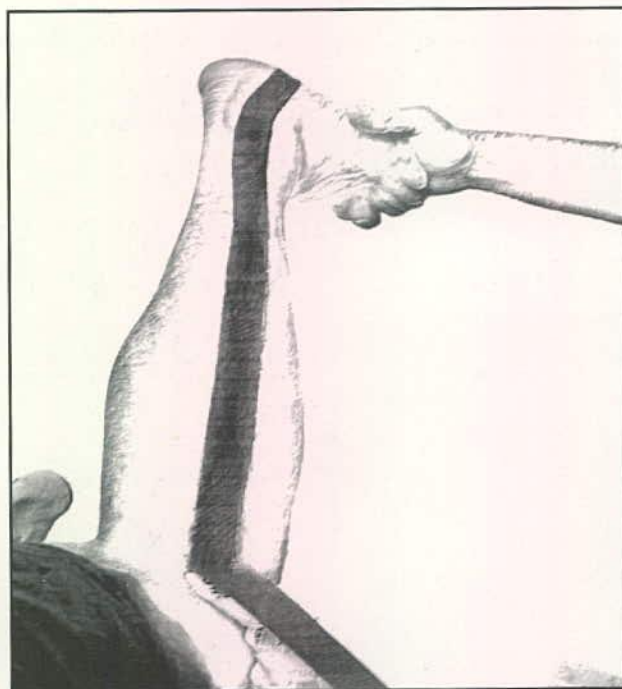
1 Patient in sidelying, both legs relaxed with ankles loosely plantar flexed.



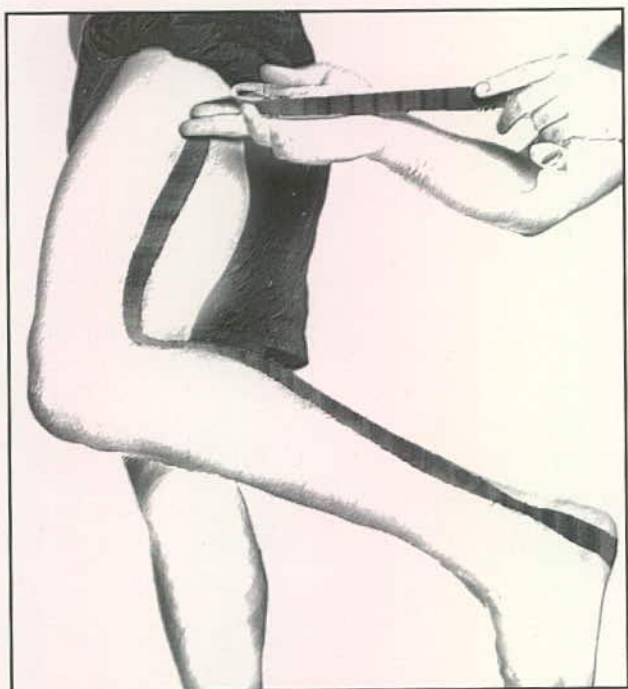2 First, with ankle dorsiflexed, adhere tape to lateral surface of Achilles's tendon.



3 Next, with knee flexed adhere tape to posterior lateral surface of knee joint.



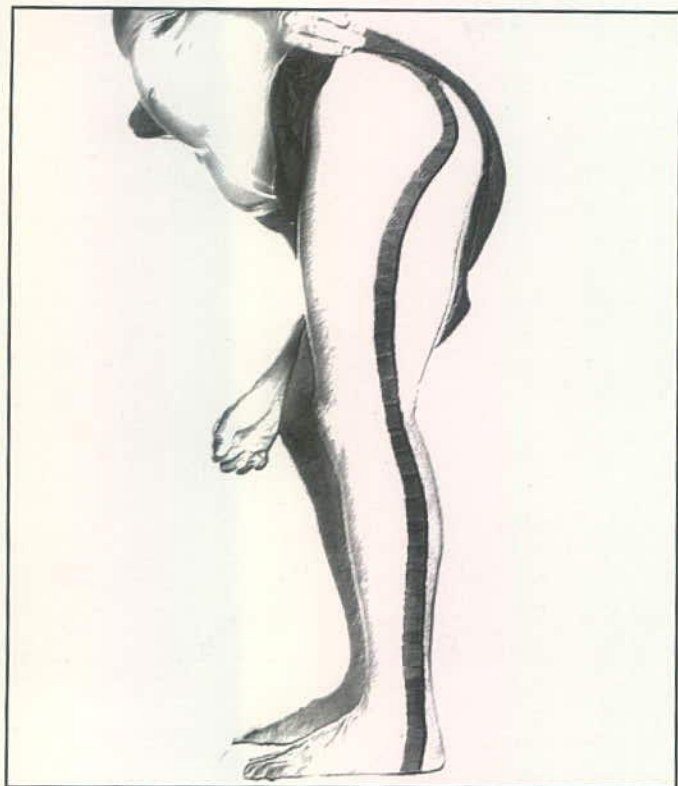
4 While extending knee affix tape along line of sciatic nerve.



5 Knee is flexed, then tape is applied to posterior lateral thigh. The tape is adhered as the knee is gradually extended.



6 Flex hip and knee, then apply tape along sciatic nerve path on buttocks. Affixed tape is affixed as hip and knee are gradually extended.




7 Continue tape application to lower lumbar vertebral column while knee and hip are flexed and trunk is flexed and side bent to opposite side.



8 The Completed Sciatic Nerve Taping.
In standing position, patient forward flexes with sciatic tape. In this position, decrease in the sciatic pain should be checked.

AUTHOR'S PROFILE

Kenzo Kase, D.C.



- 1942 Born in Tokyo, Japan
- 1965 Graduated from Meiji University, B.B.A., Tokyo
- 1974 Graduated from National College of Chiropractic, Chicago, IL
- 1975 Opened Kase Chiropractic Clinic, Albuquerque, NM
- 1978 Returned to Japan
- 1979 Opened Kase Chiropractic Clinic, Tokyo, Japan
- 1980 Invented and developed Kinesio Taping[®] Method
- 1982 Published his first book, "The Vertebrae & Chiropractic"

President of Kinesio Taping[®] Association and National Chiropractic College in Japan.

Certified D.C. in the United States and one of the best chiropractors in Japan. He invented and developed the Kinesio Taping[®] Method.

